

# Tools & Techniques: Percutaneous intervention of saphenous vein graft lesions

Pierfrancesco Agostoni<sup>1\*</sup>, MD, PhD; Michiel Voskuil<sup>1</sup>, MD, PhD; Kevin Onsea<sup>1</sup>, MD; Paul Vermeersch<sup>2</sup>, MD, PhD; Pieter R. Stella<sup>1</sup>, MD, PhD

1. Department of Cardiology, University Medical Center Utrecht, Utrecht, The Netherlands; 2. Antwerp Cardiovascular Institute Middelheim, Antwerp, Belgium

## Background

The percutaneous treatment of patients with obstructive atherosclerotic disease in coronary saphenous vein bypass grafts (SVG) remains a challenge in interventional cardiology. Patients undergoing SVG intervention are often older, and suffer significant comorbidities. Moreover, SVGs usually present a degenerated pattern of atherosclerosis, with complex, friable, thrombotic-prone lesions. SVG interventions carry a higher risk of acute complications, mainly distal embolisation, and poorer long-term outcomes, mainly restenosis, than do native coronary vessel interventions<sup>1,2</sup>. The predictors of one-month major cardiac events after SVG intervention have been explored recently<sup>3</sup>. The degree of SVG degeneration assessed by the SVG degeneration score, the estimated plaque volume, angiographic evidence of thrombus, and increasing patient age are the correlates associated with the 30-day composite outcome of death, myocardial infarction (MI) and target lesion revascularisation (TLR). Thus, an important reason for poorer outcomes of percutaneous coronary interventions (PCI) in SVGs is the embolisation of atherothrombotic debris into the native coronary circulation, often resulting in periprocedural MI or reduced antegrade flow (“no-reflow”). Strategies for addressing this distal embolisation problem include both proximal and distal protection devices, as well as adjunctive pharmacology and stenting approaches. Embolic

protection devices have demonstrated value in decreasing the risk of embolisation and post-procedural myocardial enzyme elevation after SVG intervention. While stenting has definitely been proved to be superior to balloon-only angioplasty for the treatment of SVG lesions, the choice of the type of stent (bare metal stent versus drug-eluting stent) is still a matter of debate. Drug-eluting stents appear promising for the successful sealing of SVG disease; however, available long-term safety and effectiveness data are conflicting and give reason for caution.

## Natural history of SVG disease

The SVG disease process involves three interlinked pathophysiological phenomena which lead to progressive degeneration: thrombosis, intimal hyperplasia, and atherosclerosis.

## THROMBOSIS

About 10% of SVGs occlude, with or without symptoms, within the first month after coronary artery bypass graft (CABG) surgery. This early phenomenon seems to be related to severe endothelial cell loss and medial damage during harvesting. In addition, this prothrombotic stage of SVG may be amplified by technical factors which reduce graft flow, such as intact venous valves, anastomosis stricture, and graft anastomosis proximal to diseased segments.

\*Corresponding author: University Medical Center Utrecht, Department of Cardiology, Room E.04.201, Heidelberglaan 100, 3584 CX Utrecht, The Netherlands. E-mail: agostonipf@gmail.com

## INTIMAL HYPERPLASIA

Accumulation of smooth muscle cells and extracellular matrix in the intimal space (intimal hyperplasia) is the main disease process that occurs during the first months after venous bypass grafting. The pronounced increase in wall stress by exposure to arterial pressures seems to be an important factor inducing this phenomenon. This process represents the foundation for later development of SVG atherosclerosis.

## ATHEROSCLEROSIS

In the first years after CABG, atherosclerosis is the dominant process involved in SVG disease, but recurrent symptoms due to SVG disease rarely occur before three years after grafting. Morphologically, vein graft atherosclerosis tends to be diffuse, concentric, and friable with a poorly developed or absent fibrous cap and little evidence of calcification.

## Indications

Due to the increased risk of periprocedural MI related to SVG interventions, PCI of the native grafted vessel if technically feasible is usually preferred over PCI of the degenerated SVG. However, when PCI of the native vessel is not possible the clinical benefit of a high-risk SVG intervention should be balanced against the risk of morbidity and mortality of repeat CABG. In addition, repeat CABG is less effective in terms of complete revascularisation and symptom control when compared to the first procedure. The latest updated guidelines on this topic<sup>4</sup> recommend PCI in the following circumstances:

- Early ischaemia (usually within 30 days) after CABG, when technically feasible.
- Ischaemia that occurs one to three years after CABG in patients with discrete lesions and preserved LV function. It is also reasonable in patients with diseased SVGs older than three years and, if feasible, in patients with patent left internal mammary artery (IMA) and significant obstruction in other vessels.
- PCI is not recommended in patients with total SVG occlusions, or multiple target lesions (native/SVG disease) and impaired LV function, unless repeat CABG poses excessive risk.
- CABG is usually reserved for patients who cannot have adequate percutaneous revascularisation or for those who may gain an additional benefit from CABG, such as those with previously unused left IMA to left anterior descending artery.

In summary, PCI is usually preferred over repeat CABG for early recurrent symptoms after CABG (<3 years). For late graft failure, because of the initial higher mortality of redo CABG and the comparable long-term mortality, PCI is the preferred revascularisation strategy in patients with patent left IMA and amenable anatomy. However, most symptomatic post-CABG patients present with extensive native and graft disease where the revascularisation strategy must be based on careful risk/benefit assessment of the procedure and the local experience. The most important factors involved in the choice of repeat CABG are more extensive SVG/native disease, lower left ventricular ejection fraction, longer interval from

first CABG, more total occlusion of native arteries, and the absence of patent IMA graft. The IMA is the conduit of choice for revascularisation during redo CABG.

## Difficulties and methods

When dealing with a percutaneous intervention for an SVG lesion, pharmacological pre-treatment of the patient is important. Dual antiplatelet therapy (with a thienopyridine given upfront) and statins are mandatory, unless clearly contraindicated. Periprocedural glycoprotein IIb/IIIa inhibitors do not seem to be effective in SVG interventions<sup>5</sup>. However, in cases of acute myocardial infarction due to acute graft closure and the possibly high burden of acute, non-organised thrombus, we still suggest using these drugs.

## ACCESS SITE AND GUIDING CATHETER CHOICE

For SVG there is no specific reason to choose either the radial or the femoral approach besides the known risks/benefits of each access site, the choice of the patient and the experience of the operator. In our experience, when using radial access, a left radial approach is more suitable for SVG, originating from the left anterior wall of the aorta and directed to the left coronary artery. For these SVG, mainly if their aortic anastomosis is high in the ascending aorta, the right radial approach offers poor support and the choice of the guiding catheter remains complicated and poorly predictable. On the other hand, for SVG from the right or posterior wall of the aorta (usually directed to the right coronary artery or sometimes to the circumflex territory) right and left radial approaches are equivalent. Choosing the correct guiding catheter is a very important step. In our experience, for SVG to the right coronary artery, originating most of the time from the right anterior surface of the aorta, the multipurpose catheter has the best alignment and support when performing the procedure via either the femoral or the radial artery. Engagement of the catheter can be performed in the left anterior oblique view. For vein grafts originating from the left anterior surface (usually to the left anterior descending/diagonal or marginal/circumflex arteries), we prefer Judkins right or left coronary bypass catheters (the best fitting catheter can be tested during the diagnostic angiography) in case of femoral access. If additional support is needed, Amplatz left catheters can be used. Engagement is feasible in the right anterior oblique view. When approaching these bypasses via the radial approach, as previously mentioned, we recommend choosing the left radial artery. Guiding catheters of choice can be extra back-up-shaped or Amplatz left catheters. Sometimes vein grafts to the circumflex originate from the posterior surface of the aorta. In this case, Amplatz left or multipurpose guiding catheters are preferred, and engagement is performed in the right anterior oblique view.

## EMBOLIC PROTECTION

The “mechanical” protection of the vasculature distal to the treated SVG lesion is the only strategy, up to now, soundly proven to reduce distal embolisation and periprocedural MI. Indeed PCI of SVG should always be performed under embolic protection device. So far, three types of device have been developed with this scope.

The first to be tested in SVG was a distal occlusion device (Figure 1-Figure 3). Its mechanism is as follows. A compliant balloon, directly present in the distal tip of a guidewire specifically made with this feature, is positioned distal to the lesion before the PCI and is inflated at low pressure during the procedure (using a dedicated device that introduces water through the special wire

itself), creating a temporary occlusion of the vessel. Suction of the stagnant blood/debris is done just after the PCI using an aspiration catheter inserted through the guiding catheter over the special wire, and the balloon is then deflated. In the randomised Saphenous Vein Graft Angioplasty Free of Emboli Randomized (SAFER) trial, this device was shown to reduce significantly the incidence of major

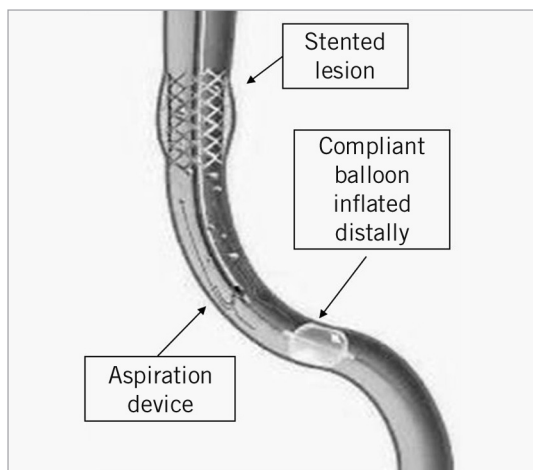


Figure 1. Distal occlusion device, graphical representation.

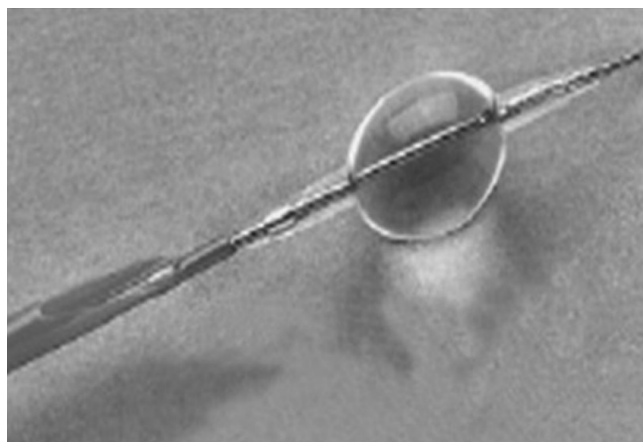


Figure 2. Distal occlusion device (PercuSurge GuardWire; Medtronic Inc., Minneapolis, MN, USA).

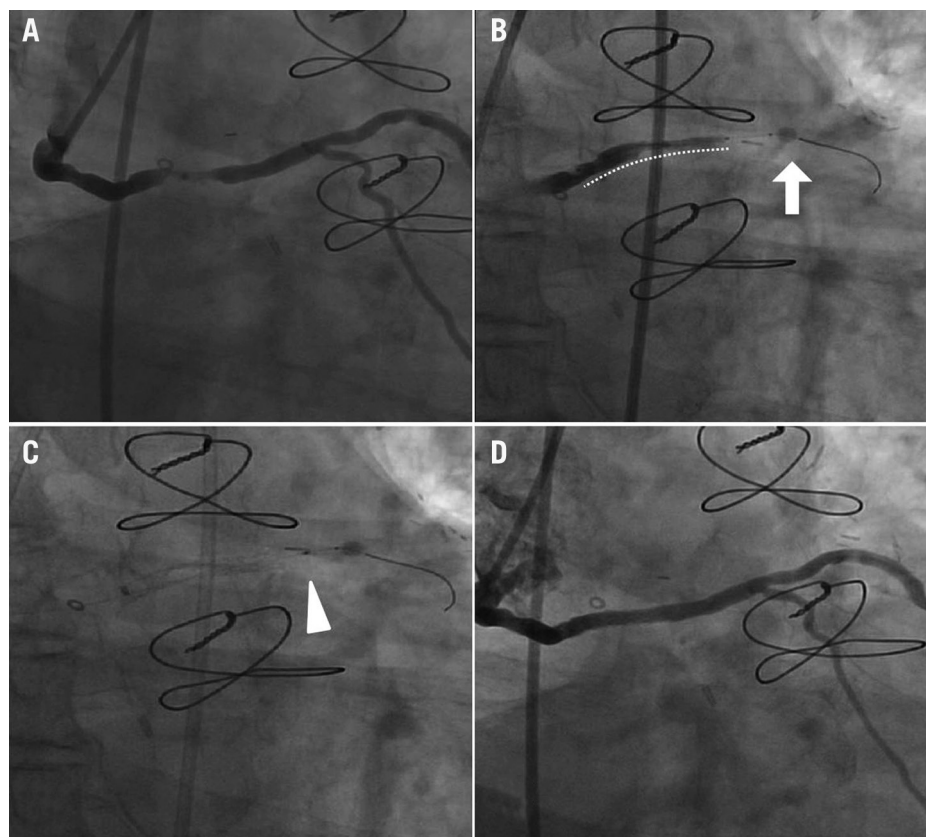
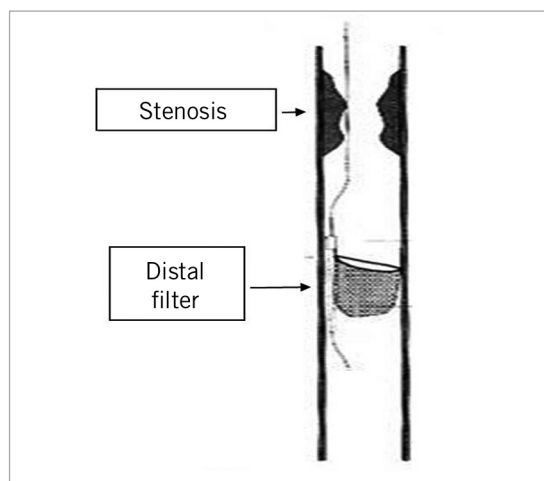


Figure 3. Distal occlusion device mechanism of action: A) Severe stenosis in the mid portion of a saphenous vein graft to the left circumflex coronary artery. B) Distal occlusion non-compliant balloon inflated (arrow) with a stent positioned at the level of the lesion (dotted line). C) Manual debris aspiration (the arrowhead indicates the tip of the aspiration catheter) still with inflated distal occlusion balloon in place. D) Final result.

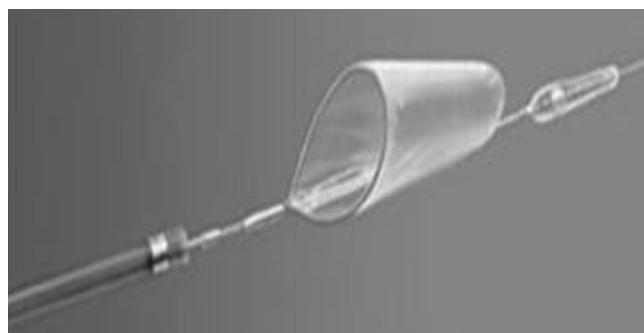adverse clinical events at 30 days compared to the simple implantation of stent without distal protection. This benefit was largely driven by a reduction in the rate of periprocedural MI<sup>6</sup>. A second distal occlusion device has also been tested effectively and is available on the market<sup>7</sup>.

Distal filters have the same rationale but a different mechanism of action from the distal occlusion device (**Figure 4-Figure 6**). A distal filter is a porous filter, which is placed distally to the lesion before the PCI in order to collect embolic material and retrieve it after the procedure. The value of the first commercialised filter has been proven in the Filterwire Randomized Evaluation (FIRE) trial, a large randomised study, in which the filter was shown to be non-inferior to the previously described “occlusion and aspiration” system<sup>8</sup>. Several filters have recently been released onto the market, some with proven non-inferiority as compared with the approved protection devices<sup>9</sup>, some without clear evidence of benefit<sup>10,11</sup>.

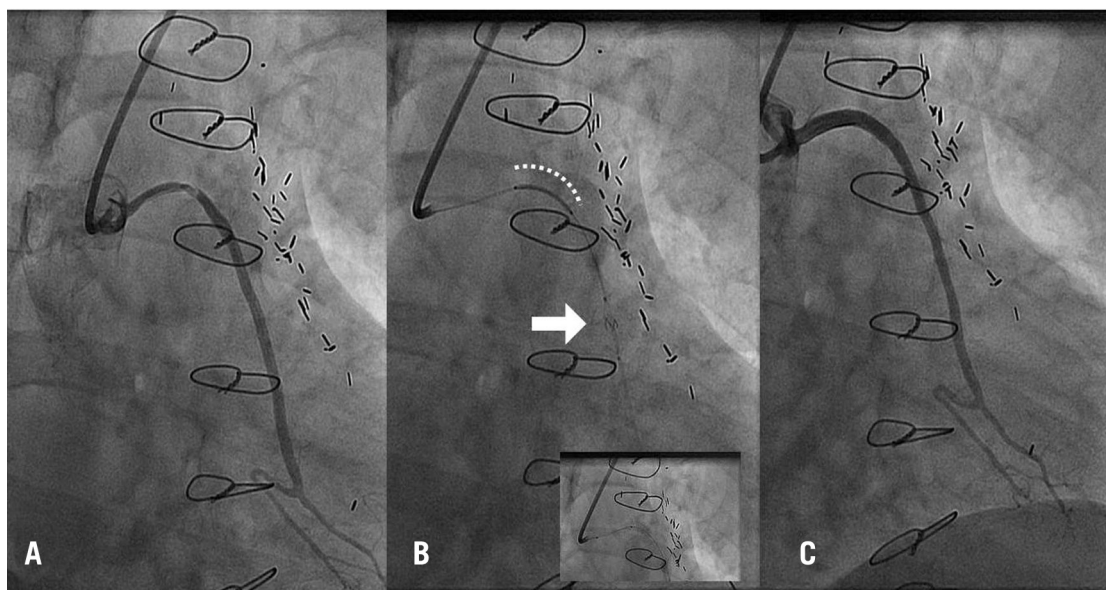
The last embolic protection device is the proximal protection device (**Figure 7-Figure 9**). This is a catheter with a specific protection balloon on its distal tip, guided inside a standard guiding catheter up to the ostium of the vein graft proximal to the lesion site (similar to a mother-and-child technique). At this level the balloon is inflated temporarily, occluding blood flow and creating a column of stagnant blood, so that the debris dislodged during the PCI (which is performed through the device itself) can then be aspirated from the vessel through the same catheter. The Proximal Protection During Saphenous Vein Graft Intervention Using the Proximal Embolic Protection System (PROXIMAL) trial compared this proximal protection device with currently available distal protection devices (either occlusion-based or filters) showing non-inferiority of the study device<sup>12</sup>.



**Figure 4.** Distal filter, graphic representation.



**Figure 5.** Distal filter (FilterWire EX<sup>®</sup>; Boston Scientific, Natick, MA, USA).



**Figure 6.** Distal filter mechanism of action: A) long severe proximal stenosis of a saphenous vein graft to the left circumflex coronary artery. B) distal filter (arrow) (Emboshield; Abbott Vascular, Redwood City, CA, USA) and stent in place (dotted line). In the small bottom left quadrant, a second stent is deployed in proximal overlap with the first one, still with the filter in place. C) Final result.



Despite this large body of evidence and the guidelines, embolic protection devices remain underutilised in daily practice. The elevated cost of these devices seems to be a major explanation for their low utilisation. Moreover, the fact that there is a learning curve can also play a role in the speed of their adoption in clinical practice. We recommend that operators select a couple of embolic protection devices which they can utilise regularly to build up experience with and confidence in their use. Protection devices can eventually be avoided in cases of very focal lesions in small (<3.5 mm) grafts. In this case, a soft-tip coronary guidewire and direct stenting without predilatation and post-dilatation should be the recommended strategy. Choosing the type of protection device depends mainly on the location of the lesion, on the tolerance of the patient to prolonged ischaemia and on the operator's personal experience with the device. In cases of proximal or ostial lesions, distal protection devices should be recommended. In cases of distal lesions, a proximal protection device fits better. The theoretical background for these choices relies on the fact that every protection device needs a vein graft disease-free landing zone of around 3-5 cm. In case of lesions in the mid body of the graft, any type of protection device is usable. In this instance, an important consideration for the choice of the device is the tolerance of the patient to ischaemia. Indeed, proximal protection devices and distal occlusion devices require a prolonged time of ischaemia (in our experience, usually two to four minutes) due to the temporary occlusion of the SVG by means of the inflated low-compliance balloon. On the contrary, filters allow performance of the procedure without interruption of blood flow and should be preferred in more unstable patients with poorer left ventricular function, or in SVG with a very large area of myocardium downstream.

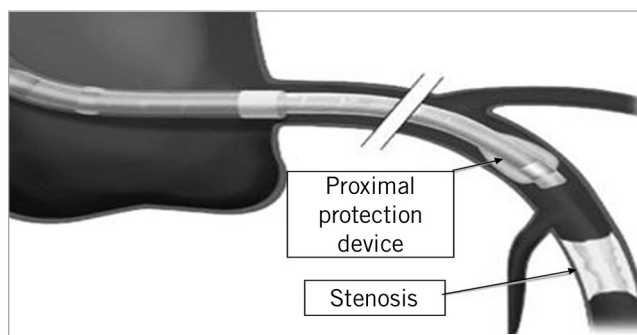


Figure 7. Proximal occlusion device, graphic representation.




Figure 8. Proximal occlusion device (Proxis; St. Jude Medical, St. Paul, MN, USA).

When using a protection device, the careful positioning of the device itself (the low-compliance balloon or the filter) in an angiographically disease-free zone is the first step. If possible, the proximal protection device can be tracked in the SVG to approximate the lesion, thus improving the support of the catheter itself for the

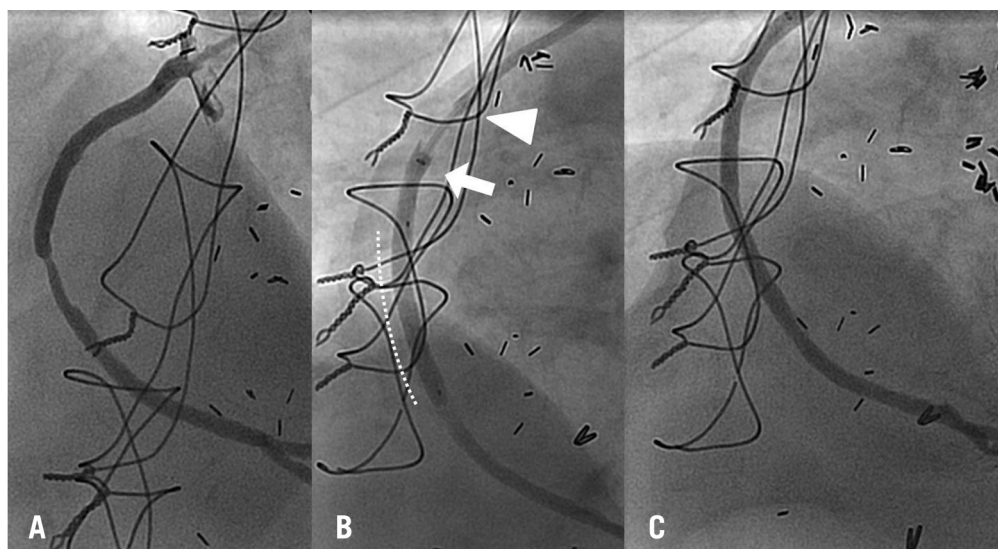


Figure 9. Proximal occlusion device mechanism of action: A) severe stenosis in the mid portion of a saphenous vein graft to the right coronary artery. B) proximal protection device in place with balloon inflated (arrow: distal tip of the device, where the non-compliant balloon is; arrowhead: distal tip of the guiding catheter) and stent in place and inflated (white dotted line). Note the stagnant column of contrast before and after the inflated stent. C) Final result.

procedure. In case of proximal or distal occlusion protection devices, the effectiveness of adequate and complete vessel occlusion should be assured. This means that a column of stagnant blood (checked with contrast) should be evident once the device is in place and inflated. If a filter is used, we recommend securing appropriate deployment of the filter (good apposition to the vessel wall) in two orthogonal views. An additional tip, in case of filter use and in case of a poorly supportive guiding catheter, is to place an additional conventional coronary guidewire in the SVG before placing the filter. This helps to stabilise the system and improves trackability of subsequent devices. Once the protection device is in place, we always recommend direct stenting and, in case the stent remains significantly underdeployed, high-pressure post-dilatation must be done with a protection device in place.

Once the stenting procedure is finished, care should be given to the collection of debris from the protection device and to retrieval of the device itself. With proximal device placement, direct aspiration of at least 5 cc of blood from the device should be performed before releasing the occlusion. In case of distal occlusion device use, the specific manual aspiration device should be used, and two syringes of 20 cc of blood should be aspirated. If a filter is used, careful, complete closure of the filter with a dedicated retrieval catheter is necessary before retrieval of the filter. We recommend performing the complete procedure under fluoroscopy. Final angiographic control of the stenting procedure without a device in place is mandatory in at least two orthogonal views.

Although definitive data coming from randomised trials are lacking, “pharmacologic” protection targeted at improving microvascular flow dynamics with intra-graft administration of vasodilators (such as adenosine, nitroprusside, verapamil or nicardipine) is considered another possible prophylactic treatment for the prevention of no-reflow. Currently, due to the lack of clear evidence about these agents, we do not perform routine prophylactic administration of these agents before SVG PCI, but only as “bail-out” in case of proven no-reflow just after PCI.

## Stent choice

While stenting has been definitely proven superior to balloon-only angioplasty in SVG intervention<sup>13</sup>, the specific type of stent (bare metal or drug-eluting) is still a matter of debate. In almost all pivotal randomised trials, SVG lesions were excluded. The mechanisms of the in-stent restenotic process in SVG are different when compared to native arteries. Furthermore, the problem of higher local prothrombotic conditions in SVG and the expected delay in endothelial healing after drug-eluting stent (DES) placement are claimed to be possible drawbacks of DES implantation in SVG, as they can potentially lead to a higher risk of stent thrombosis. Thus, clear and available data concerning the safety and the efficacy of these devices in SVG are needed before a routine application of DES in this lesion subset can be approved.

There are currently three randomised studies specifically performed in SVG: the single-centre double-blind “Reduction of Restenosis In Saphenous vein grafts with Cypher stent” (RRISC) trial, comparing in 75 patients sirolimus-eluting stents and the

respective uncoated bare metal stents (BMS)<sup>14</sup>, the multicentre single-blind “Stenting of Saphenous Vein Grafts” (SOS) trial, comparing in 80 patients paclitaxel-eluting stents and the respective uncoated BMS<sup>15</sup>, and the multicentre “Is Drug-Eluting-Stenting Associated with Improved Results in Coronary Artery Bypass Grafts” (ISAR CABG) trial comparing in 610 patients three different DES (sub-randomised to paclitaxel-eluting stents, permanent-polymer sirolimus-eluting stents, or biodegradable-polymer sirolimus-eluting stents) versus BMS<sup>16</sup>.

All these trials showed significant reduction of angiographic and clinical restenosis with DES compared with BMS at one-year follow-up. However, longer-term follow-up *post hoc* analyses of the RRISC and of the SOS trials showed conflicting clinical results. The SOS trial reported sustained benefit, with DES significantly reducing repeated revascularisation procedures without any significant difference in mortality<sup>17</sup>. The RRISC trial showed a notable increase in mortality with DES, also with attrition in revascularisation difference that disappeared at three-year follow-up<sup>18</sup>. The long-term results of the much larger ISAR CABG trial are eagerly awaited and will shed additional light on the topic.

At a lower level of evidence with respect to randomised trials, several registries have assessed the mid-term and long-term safety and effectiveness of DES in SVG<sup>19</sup>. Overall, while in all studies with follow-up <1 year the benefits of DES in terms of reduction of repeated revascularisation procedures seem evident, at longer term several studies have not shown significantly different revascularisation outcomes between DES and BMS, while a few studies have demonstrated only moderate advantages, clearly not comparable to the benefits shown in native coronary arteries. On the other hand, safety issues, such as those seen in the long-term follow-up of the RRISC trial, have never been confirmed.

All these data underline the fact that DES can be considered effective and safe at short-term (one year) follow-up as consistently shown in several studies; however, longer-term follow-up of adequately performed studies is required to confirm that DES remain safe and effective also after one year. While awaiting these studies, our policy is to implant BMS as first choice for *de novo* SVG lesions and, in case of restenosis, which in any case has a different, less thrombus-prone physiopathological substrate than native vein graft disease, DES.

Concerning the implantation strategy, independently from the type of stent chosen, we almost always definitely recommend attempting direct stenting. In case of failure, we also suggest a low threshold for switching to balloon predilatation. Significantly undersized balloons should be favoured in case of predilatation in order to minimise plaque embolisation. In case of temporary occlusion of the SVG during direct stent placement and the impossibility of visualising with contrast the distal landing zone of the SVG, the clips present around the SVG can often be used as landmarks to improve accuracy in stent positioning and deployment, even without the help of contrast injections.

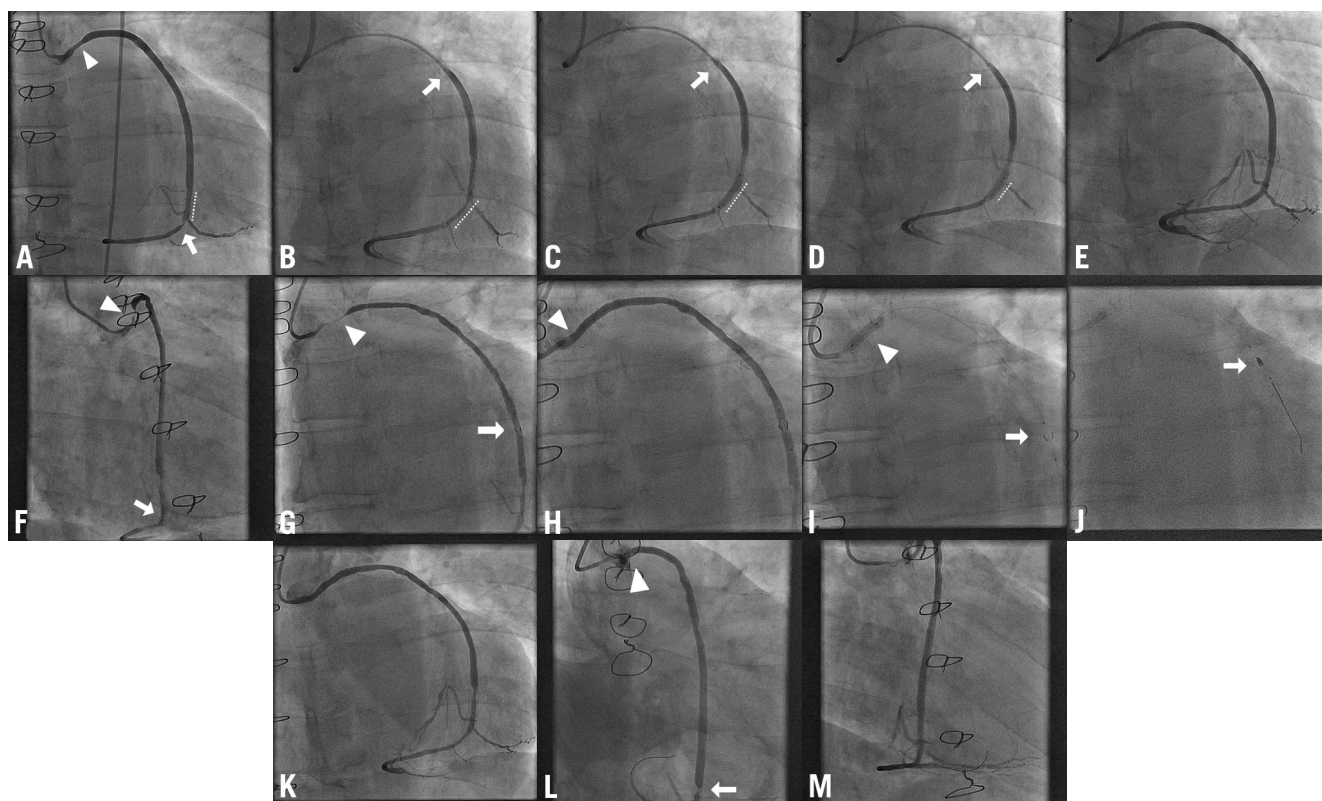
Other types of stent, so-called “covered” stents, have also been tested in SVG lesions. The rationale behind this type of stent was to prevent distal embolisation, as the stent itself, covered by a layer of

polytetrafluoroethylene (PTFE), was supposed to trap friable plaque between the stent and the SVG wall. However, this theory proved false: PTFE-covered stents, in comparison to BMS, did not reduce the amount of distal embolisation and the rate of periprocedural MI, and showed no different, or even worse, clinical and angiographic restenosis<sup>13</sup>. Thus, the use of PTFE-covered stents in the treatment of SVG cannot be recommended. Nonetheless, new developments in the same concept have recently been undertaken. Preliminary experience using a newly developed system comprising a BMS platform with a polymeric net attached to its surface (supposedly able to entrap fibro-thrombotic material), appears to be a potentially interesting innovation to prevent distal embolisation

and no-reflow in SVG PCI<sup>20</sup>. However, these data are preliminary and based on a small number of patients: once again, therefore, larger trials are definitely needed. In the meanwhile, this device should be used only in the setting of clinical studies.

### Plaque sealing in SVG

Atherosclerosis in SVG is known to be markedly accelerated. The progression, in the short term, of SVG segments from previously non-significant lesions to new severe stenoses accounts for a considerable rate of SVG failure post PCI (Figure 10A-Figure 10M). Thus, the idea of treating SVG lesions before they become ischaemic (“plaque sealing”) definitely remains appealing in SVG. This



**Figure 10.** Representative patient with previous coronary artery bypass surgery, undergoing multiple percutaneous coronary interventions (PCI), using different embolic protection devices, in a short period of time. A) April 2009: jump saphenous vein graft (SVG) to the obtuse marginal (OM) branch and to the posterior descending artery, showing a moderate lesion proximally (arrowhead), a good result of a previously placed stent just before the anastomosis with the OM branch (dotted line), and a severe lesion just after the same anastomosis (arrow). B) Direct stenting of this lesion (dotted line) using the proximal protection device (the arrow indicates the inflated compliant balloon temporarily occluding the SVG). C) Stent inflation (dotted line) under proximal protection device (arrow). D) High pressure post-dilatation of the stent (dotted line), once again under proximal protection device (arrow). E) Final angiogram showing a good result of the stent and TIMI 3 flow distally. F) May 2010: progression of the disease in the proximal part of the same SVG (arrowhead), with good result of the stent implanted in 2009 (arrow). G) Placement of a distal filter as embolic protection device (arrow) after the lesion (arrowhead). H) Angiographic result after direct stenting of the lesion: residual underexpansion is evident (arrowhead). I) High pressure post-dilatation of the stent (arrowhead), keeping the filter in place (arrow). J) Retrieval of the filter by means of a dedicated retrieval catheter that allows closure of the filter before pulling it back into the guiding catheter (arrow). K) Final angiogram showing a good result of the stent and TIMI 3 flow distally. L) February 2011: good result of the stents implanted in 2009 (distally to the anastomosis with the OM branch, poorly visible in this figure) and in 2010 (in the ostial proximal segment of the SVG, arrowhead), but clear progression of the disease in a stent (“late in-stent restenosis”) placed previously in the same SVG just before the anastomosis with the OM branch and already present in 2009 (arrow). M) Final angiogram after treatment with drug-eluting balloon, showing a good result at the level of the lesion and TIMI 3 flow distally.



interesting concept has been tested in the small randomised “Moderate VEin Graft LEsion Stenting with the Taxus stent and Intravascular ultrasound” (VELETI) pilot trial with promising results<sup>21</sup>. A 22% rate of progression from moderate non-ischaeamic lesions to clinically severe stenoses was shown in only one year in the group treated conventionally, with medical therapy only. This indeed proves the rapidly evolving nature of SVG disease. In our routine, we tend to treat lesions in SVG in case they are angiographically >50% (and in case the PCI is technically feasible with an *a priori* low chance of having major complications), independently from the presence of proven ischaemia in the specific myocardial territory vascularised by the diseased SVG.

### Conflict of interest statement

The authors have no relevant affiliations or financial involvement with any organisation or entity with a financial interest in or financial conflict with the subject matter or materials discussed in the manuscript. This includes employment, consultancies, honoraria, stock ownership or options, expert testimony, grants or patents received or pending, or royalties. No writing assistance was utilised in the production of this manuscript.

### References

1. Frimerman A, Rechavia E, Eigler N, Payton MR, Makkar R, Litvack F. Long-term follow-up of a high risk cohort after stent implantation in saphenous vein grafts. *J Am Coll Cardiol.* 1997;30:1277-83.
2. Pucelikova T, Mehran R, Kirtane AJ, Kim YH, Fahy M, Weisz G, Lansky AJ, Moussa I, Gray WA, Collins MB, Kodali SK, Stone GW, Moses JW, Leon MB, Dangas G. Short- and long-term outcomes after stent-assisted percutaneous treatment of saphenous vein grafts in the drug-eluting stent era. *Am J Cardiol.* 2008;101:63-8.
3. Coolong A, Baim DS, Kuntz RE, O'Malley AJ, Marulkar S, Cutlip DE, Popma JJ, Mauri L. Saphenous vein graft stenting and major adverse cardiac events: a predictive model derived from a pooled analysis of 3958 patients. *Circulation.* 2008;117:790-7.
4. Task Force on Myocardial Revascularization of the European Society of Cardiology (ESC) and the European Association for Cardio-Thoracic Surgery (EACTS); European Association for Percutaneous Cardiovascular Interventions (EAPCI), Wijns W, Kolh P, Danchin N, Di Mario C, Falk V, Folliguet T, Garg S, Huber K, James S, Knuuti J, Lopez-Sendon J, Marco J, Menicanti L, Ostojic M, Piepoli MF, Pirlet C, Pomar JL, Reifart N, Ribichini FL, Schlij MJ, Sergeant P, Serruys PW, Silber S, Sousa Uva M, Taggart D. Guidelines on myocardial revascularization. *Eur Heart J.* 2010;31:2501-55.
5. Roffi M, Mukherjee D, Chew DP, Bhatt DL, Cho L, Robbins MA, Ziada KM, Brennan DM, Ellis SG, Topol EJ. Lack of benefit from intravenous platelet glycoprotein IIb/IIIa receptor inhibition as adjunctive treatment for percutaneous interventions of aortocoronary bypass grafts: a pooled analysis of five randomized clinical trials. *Circulation.* 2002;106:3063-7.
6. Baim DS, Wahr D, George B, Leon MB, Greenberg J, Cutlip DE, Kaya U, Popma JJ, Ho KK, Kuntz RE. Randomized trial of a distal embolic protection device during percutaneous intervention of saphenous vein aorto-coronary bypass grafts. *Circulation.* 2002;105:1285-90.
7. Carrozza JP, Mumma M, Breall J, Fernandez A, Heyman E, Metzger C. Randomized evaluation of the TriActiv balloon-protection flush and extraction system for the treatment of saphenous vein graft disease. *J Am Coll Cardiol.* 2005;46:1677-83.
8. Stone GW, Rogers C, Hermiller J, Feldman R, Hall P, Haber R, Masud A, Cambier P, Caputo RP, Turco M, Kovach R, Brodie B, Hermann HC, Kuntz RE, Popma JJ, Ramee S, Cox DA. Randomized comparison of distal protection with a filter-based catheter and a balloon occlusion and aspiration system during percutaneous intervention of diseased saphenous vein aorto-coronary bypass grafts. *Circulation.* 2003;108:548-53.
9. Kereiakes DJ, Turco MA, Breall J, Farhat NZ, Feldman RL, McLaurin B, Popma JJ, Mauri L, Zimetbaum P, Massaro J, Cutlip DE. A novel filter-based distal embolic protection device for percutaneous intervention of saphenous vein graft lesions: results of the AMETHYST randomized controlled trial. *JACC Cardiovasc Interv.* 2008;1:248-57.
10. Dixon SR, Mann JT, Lauer MA, Casale PN, Dippel EJ, Strumpf RK, Feldman RL, Shear W, Resar JR, Zimmer SD, O'Neill WW. A randomized, controlled trial of saphenous vein graft intervention with a filter-based distal embolic protection device: TRAP trial. *J Interv Cardiol.* 2005;18:233-41.
11. Holmes DR, Coolong A, O'Shaughnessy C, Chauhan M, Van Langenhove G, Hall P, Vermeersch P, Verlee P, Popma JJ, Cutlip D, Kuntz RE. Comparison of the CardioShield filter with the guardwire balloon in the prevention of embolisation during vein graft intervention: results from the CAPTIVE randomised trial. *EuroIntervention.* 2006;2:161-8.
12. Mauri L, Cox D, Hermiller J, Massaro J, Wahr J, Tay SW, Jonas M, Popma JJ, Pavliska J, Wahr D, Rogers C. The PROXIMAL trial: proximal protection during saphenous vein graft intervention using the Proxis Embolic Protection System: a randomized, prospective, multicenter clinical trial. *J Am Coll Cardiol.* 2007;50:1442-9.
13. Vermeersch P, Agostoni P. Should degenerated saphenous vein grafts routinely be sealed with drug-eluting stents? *J Interv Cardiol.* 2005;18:467-73.
14. Vermeersch P, Agostoni P, Verheye S, Van den Heuvel P, Convens C, Bruining N, Van den Branden F, Van Langenhove G. Randomized double-blind comparison of sirolimus-eluting stent versus bare-metal stent implantation in diseased saphenous vein grafts: six-month angiographic, intravascular ultrasound, and clinical follow-up of the RRISC Trial. *J Am Coll Cardiol.* 2006;48:2423-31.
15. Brilakis ES, Lichtenwalter C, de Lemos JA, Roesle M, Obel O, Haagen D, Saeed B, Gadiparthi C, Bissett JK, Sachdeva R, Voudris VV, Karyofyllis P, Kar B, Rossen J, Fasseas P, Berger P, Banerjee S. A randomized controlled trial of a paclitaxel-eluting stent versus a similar bare-metal stent in saphenous vein graft lesions the SOS (Stenting of Saphenous Vein Grafts) trial. *J Am Coll Cardiol.* 2009;53:919-28.



16. Mehilli J, Pache J, Abdel-Wahab M, Schulz S, Byrne RA, Tiroch K, Hausleiter J, Seyfarth M, Ott I, Ibrahim T, Fusaro M, Laugwitz KL, Massberg S, Neumann FJ, Richardt G, Schömig A, Kastrati A. Drug-eluting versus bare-metal stents in saphenous vein graft lesions (ISAR-CABG): a randomised controlled superiority trial. *Lancet*. 2011;378:1071-8.
17. Brilakis ES, Lichtenwalter C, Abdel-karim AR, de Lemos JA, Obel O, Addo T, Roesle M, Haagen D, Rangan BV, Saeed B, Bissett JK, Sachdeva R, Voudris VV, Karyofillis P, Kar B, Rossen J, Fasseas P, Berger P, Banerjee S. Continued benefit from paclitaxel-eluting compared with bare-metal stent implantation in saphenous vein graft lesions during long-term follow-up of the SOS (Stenting of Saphenous Vein Grafts) trial. *JACC Cardiovasc Interv*. 2011;4:176-82.
18. Vermeersch P, Agostoni P, Verheye S, Van den Heuvel P, Convens C, Van den Branden F, Van Langenhove G. Increased late mortality after sirolimus-eluting stents versus bare-metal stents in diseased saphenous vein grafts: results from the randomized DELAYED RRISC Trial. *J Am Coll Cardiol*. 2007;50:261-7.
19. Testa L, Agostoni P, Vermeersch P, Biondi-Zoccai G, Van Gaal W, Bhindi R, Brilakis E, Latini RA, Laudisa ML, Pizzocri S, Lanotte S, Brambilla N, Banning A, Bedogni F. Drug eluting stents versus bare metal stents in the treatment of saphenous vein graft disease: a systematic review and meta-analysis. *EuroIntervention*. 2010;6:527-36.
20. Costa JR Jr, Abizaid A, Feres F, Costa R, Staico R, Siqueira D, Centemero M, Tanajura LF, Sousa A, Sousa JE. One-year results of the INSPIRE trial with the novel MGuard stent: serial analysis with QCA and IVUS. *Catheter Cardiovasc Interv*. 2011;78:1095-100.
21. Rodés-Cabau J, Bertrand OF, Larose E, Déry JP, Rinfret S, Bagur R, Proulx G, Nguyen CM, Côté M, Landcop MC, Boudreault JR, Rouleau J, Roy L, Gleeton O, Barbeau G, Noël B, Courtis J, Dagenais GR, Després JP, DeLarochelière R. Comparison of plaque sealing with paclitaxel-eluting stents versus medical therapy for the treatment of moderate nonsignificant saphenous vein graft lesions: the moderate vein graft lesion stenting with the taxus stent and intravascular ultrasound (VELETI) pilot trial. *Circulation*. 2009;120:1978-86.