

Reverse Left Ventricular Remodeling after Undersized Annuloplasty for Ischemic Mitral Regurgitation

Pocar, Marco¹; Moneta, Andrea²; Di Mauro, Alessandra²; Passolunghi, Davide²; Bregasi, Alda³; Clerici, Alberto³; Donatelli, Francesco³

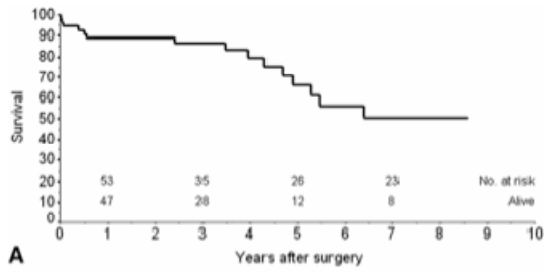
¹Università degli Studi di Milano, IRCCS MultiMedica, Sesto San Giovanni, Milano, Italy, Department of Cardiovascular & Metabolic Diseases; ²IRCCS MultiMedica, Sesto San Giovanni, Milano, Italy; ³Università degli Studi di Milano, IRCCS MultiMedica, Sesto San Giovanni, Milano, Italy

Background: Coronary artery bypass grafting (CABG) results in improved left ventricular (LV) performance and reduced ischemic mitral regurgitation (IMR). However, MR often does not resolve and correlates with a poor prognosis. Benefits of repair have been reported also in mild-to-moderate IMR, but optimal surgical treatment for intermediate-degree IMR remains widely debated.

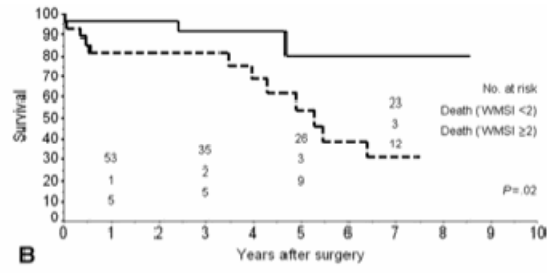
Methods: CABG combined with implantation of an undersized autologous pericardial band, or of a flexible or semirigid complete prosthetic ring was performed in 75 patients with 2+ or 3+ IMR. Longest follow-up was 10 years.

Results: Preoperative LV end-systolic volume index was the strongest predictor of early postoperative outcome at multivariable logistic regression analysis, and showed a correlation with end-systolic volume index ($p < 0.001$, $R^2 = 0.65$) and ejection fraction ($p < 0.001$, $R^2 = 0.43$) early after repair. However, a more compromised ejection fraction and end-systolic volume index at baseline predicted a comparatively greater early functional improvement, but, in parallel, a higher residual postoperative end-systolic volume index ($p < 0.01$). Wall motion score index was identified as the best baseline predictor of late death and heart failure, whereas regional infero-posterior wall motion resulted the strongest predictor of recurrent IMR at Cox multivariable analysis ($p < 0.01$). More rigid annuloplasty determined a higher probability of ejection fraction and wall motion improvement, and of the occurrence and earlier timing of LV reverse remodeling, expressed as different degrees of end-systolic volume index reduction ($p < 0.001$, hazard ratio > 5).

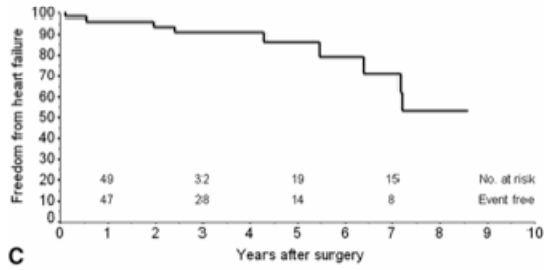
Conclusions: Undersized mitral annuloplasty combined to CABG unloads the LV in patients with intermediate-degree IMR. Global and regional wall motion predict late outcome, whereas a stiffer mitral annular stabilization promotes functional recovery and predicts higher probability and earlier timing of LV reverse remodelling.



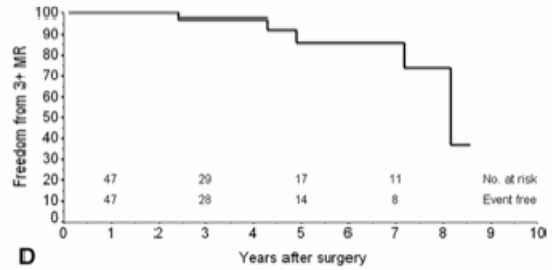
A



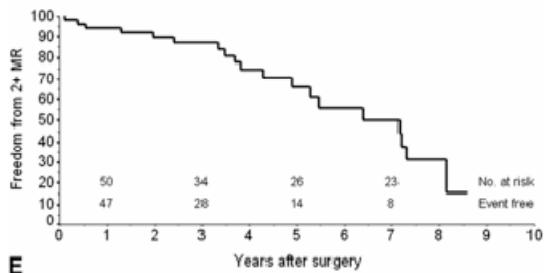
B



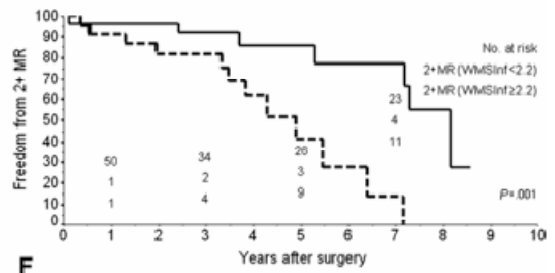
C



D



E



F