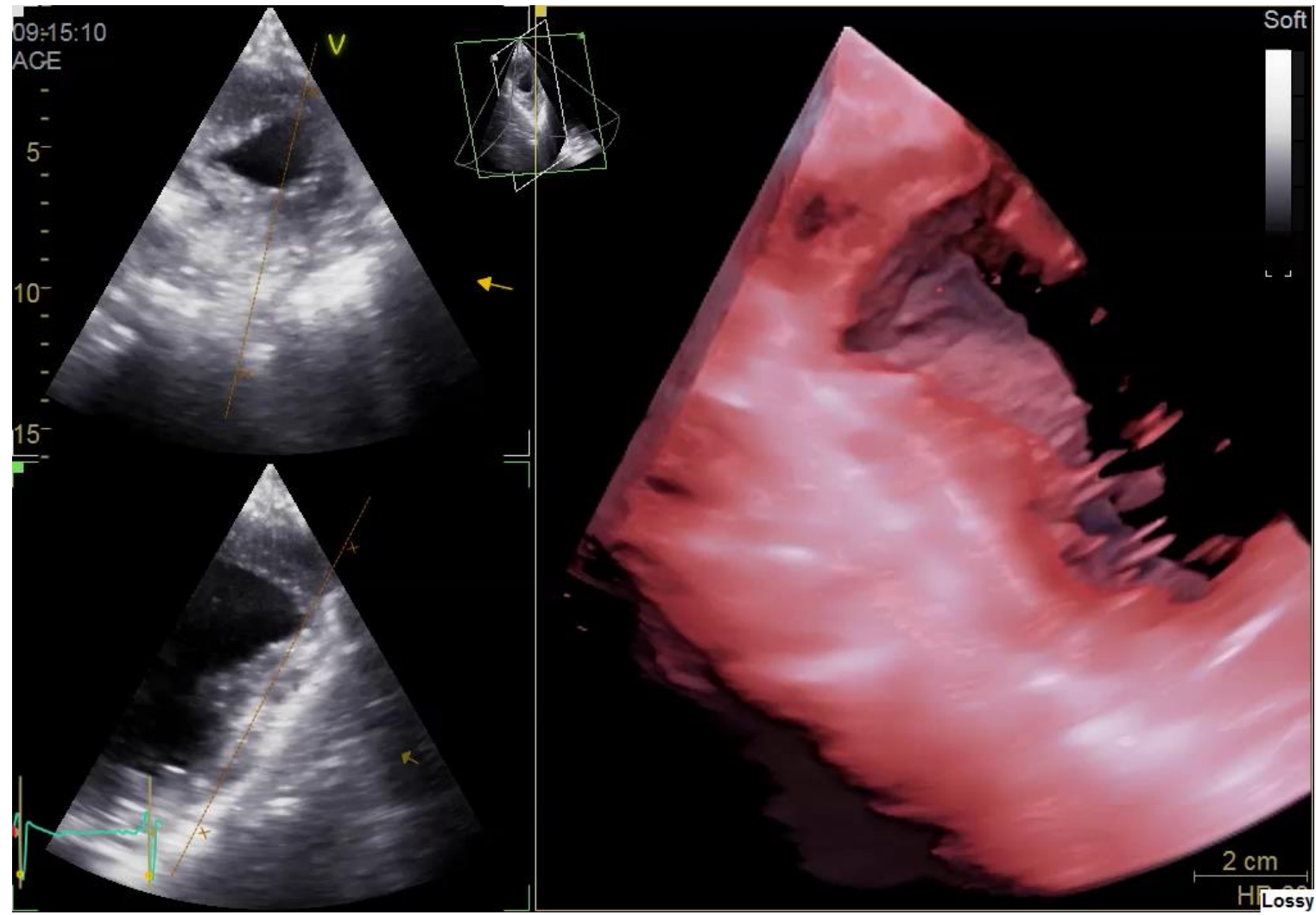
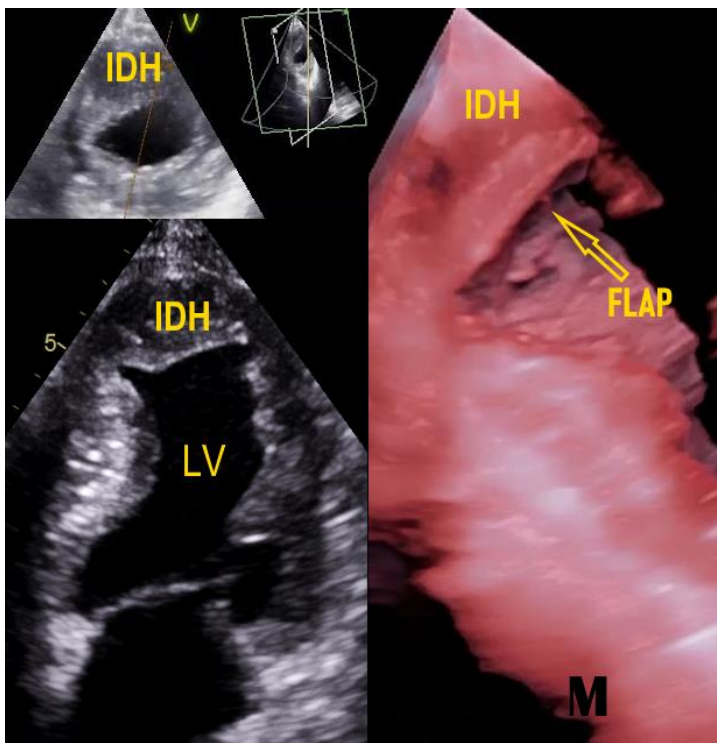
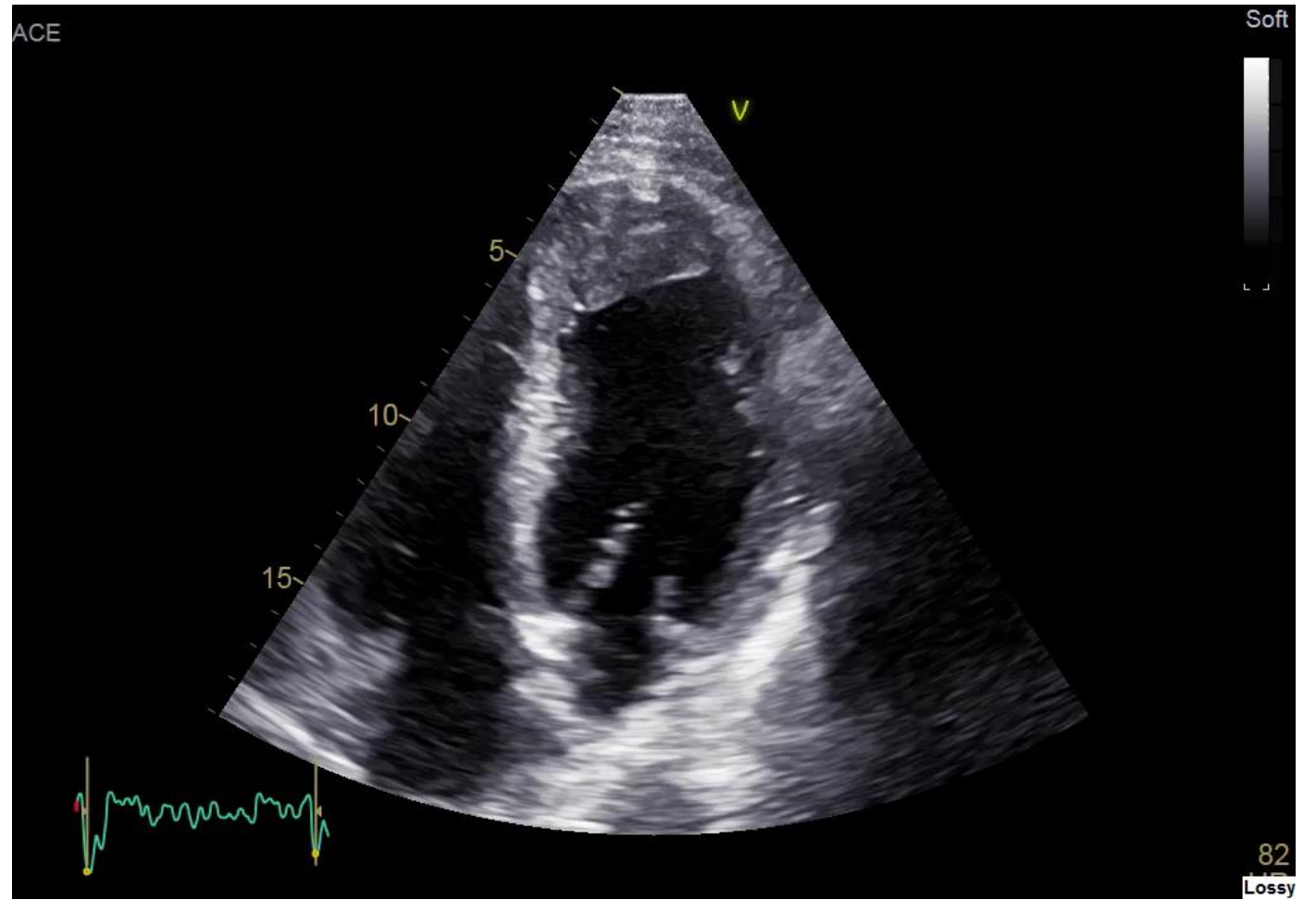
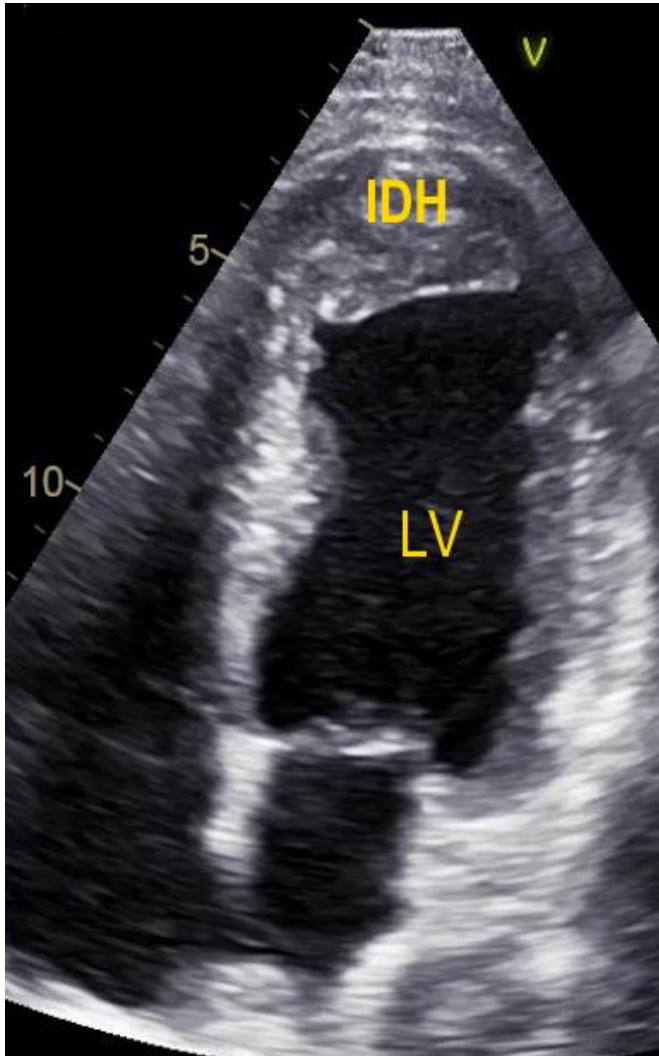


Explosion in the Heart: Outcome of Intramyocardial Dissecting Hematoma

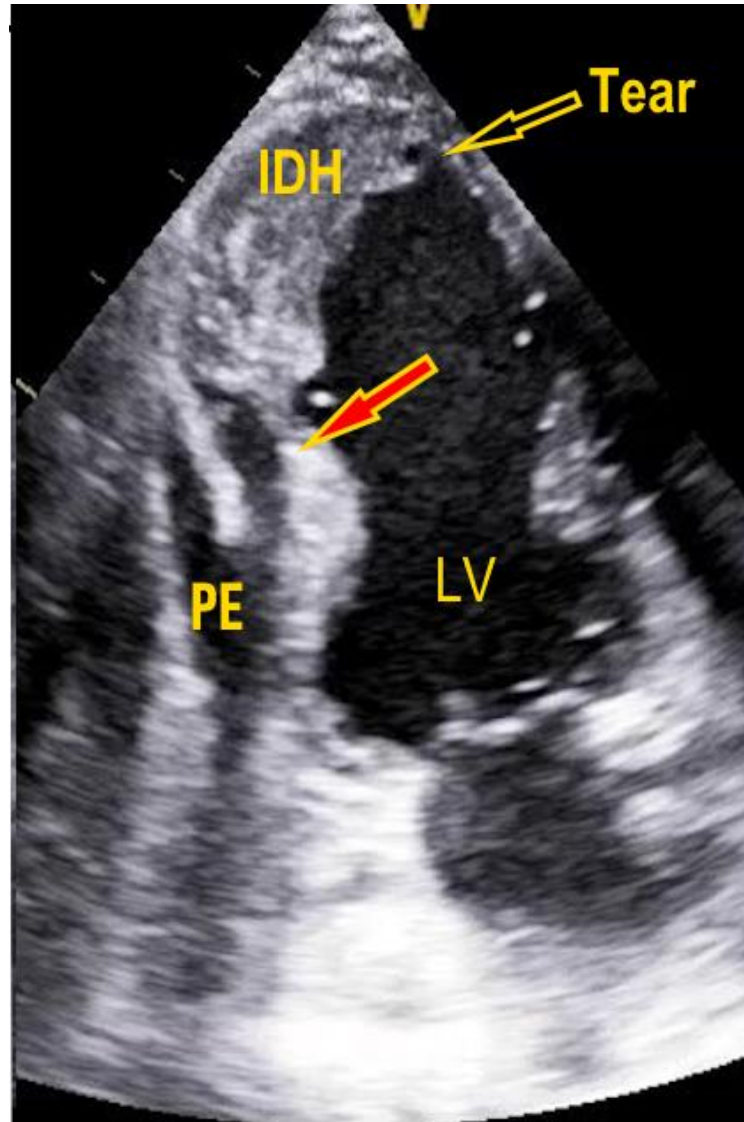
2020 – A 56 y man
Recent MI & IDH



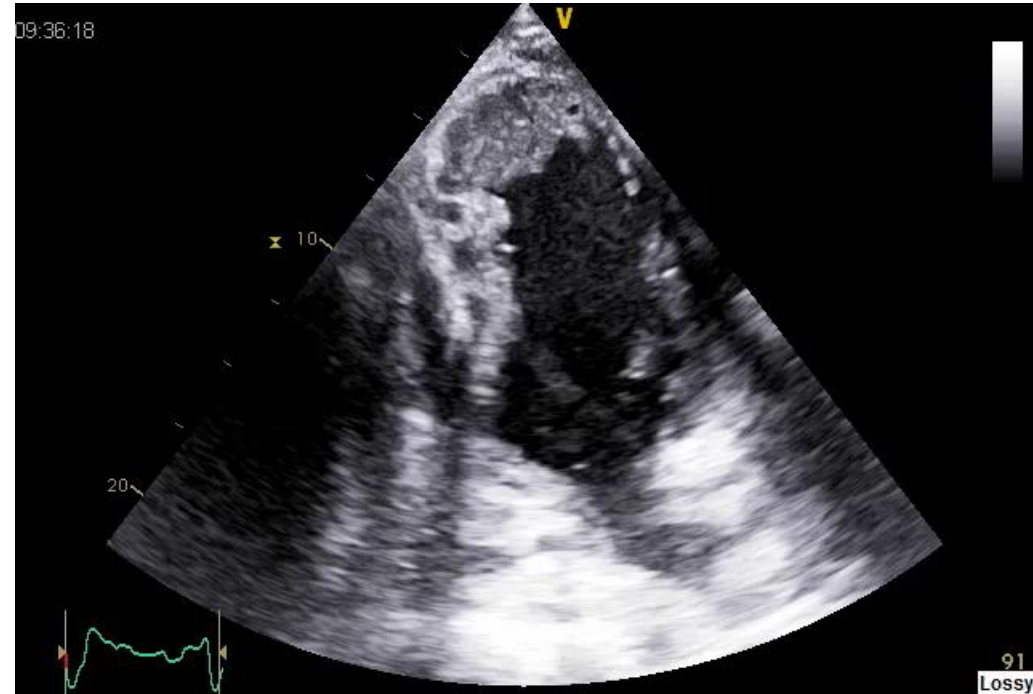2022 – Patient asymptomatic. Mass limited to Apex of LV



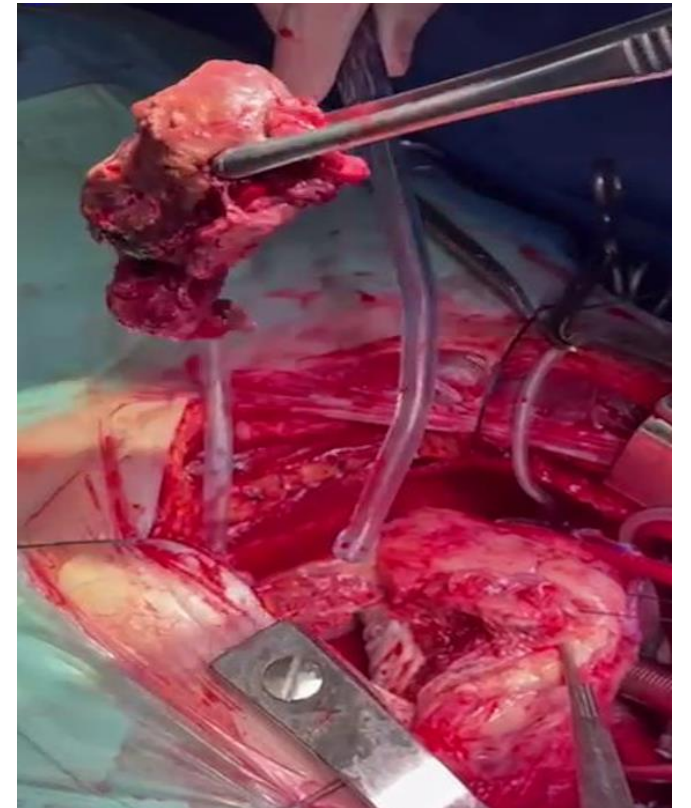
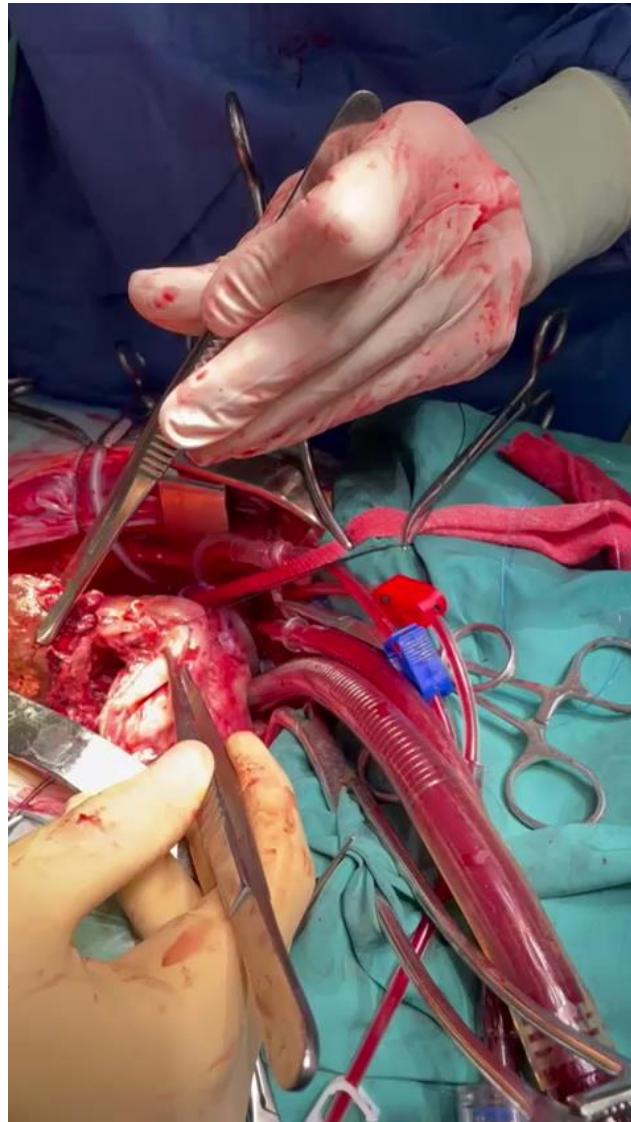
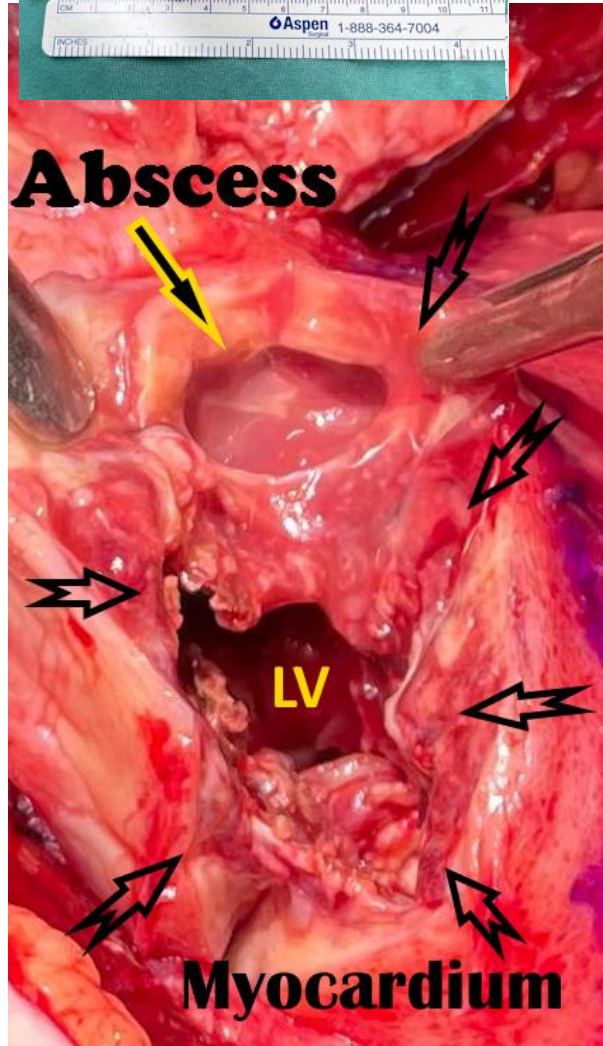
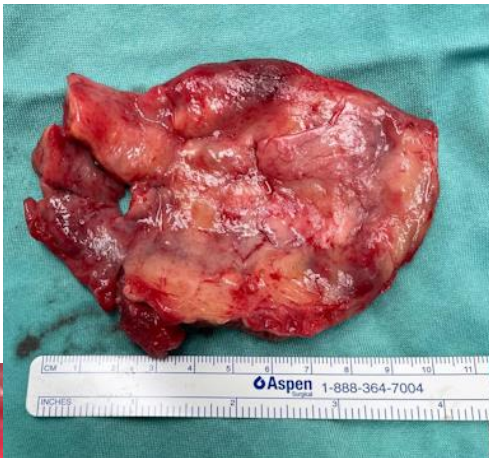2024- Sepsis - Negative work-up. Broad spectrum antibiotics.



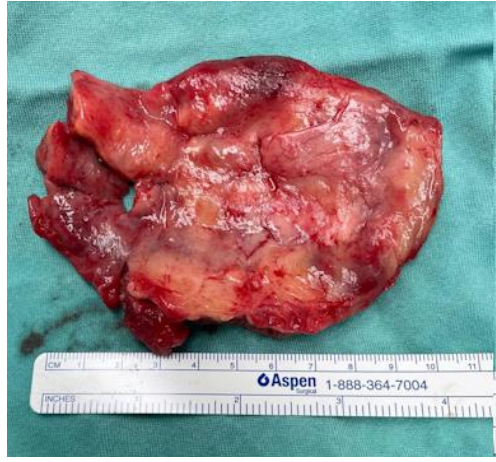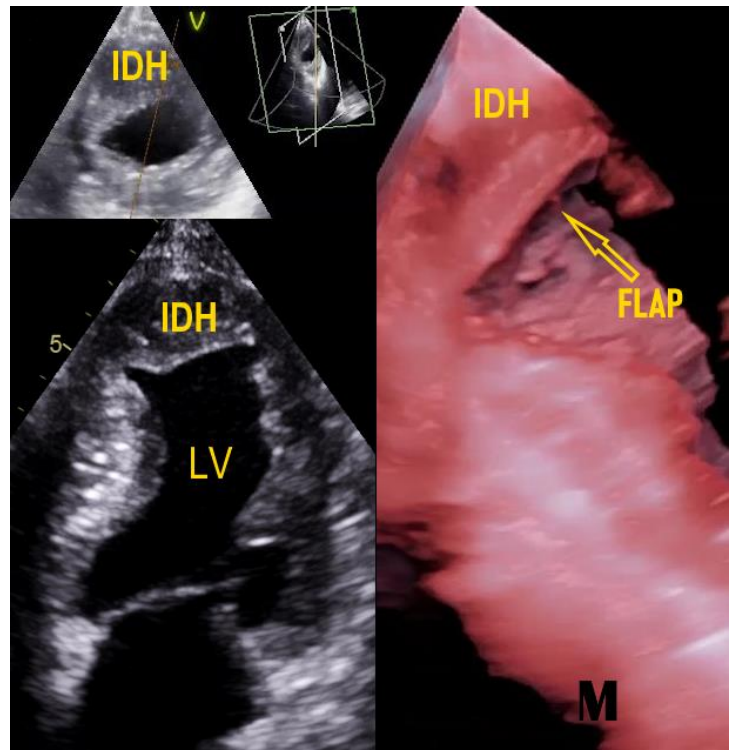
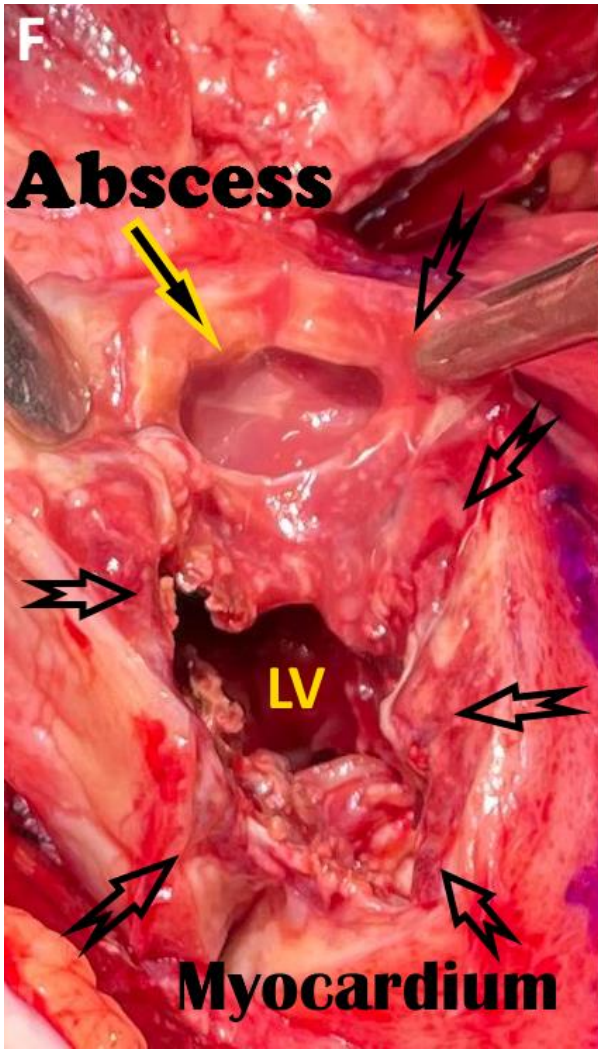
Secondary MI.



Episode of VF



PCR of the pus: Campylobacter



MI → endothelial tear & hemorrhage & enzymes → collagen disruption.

Spiral helical structure of the heart → propagation of hemorrhage.

Small hematomas → conservatively.

Extension of hematoma, PE & compromised hemodynamics → surgery.

Expansion of IDH after 4 years and abscess - highly unusual