

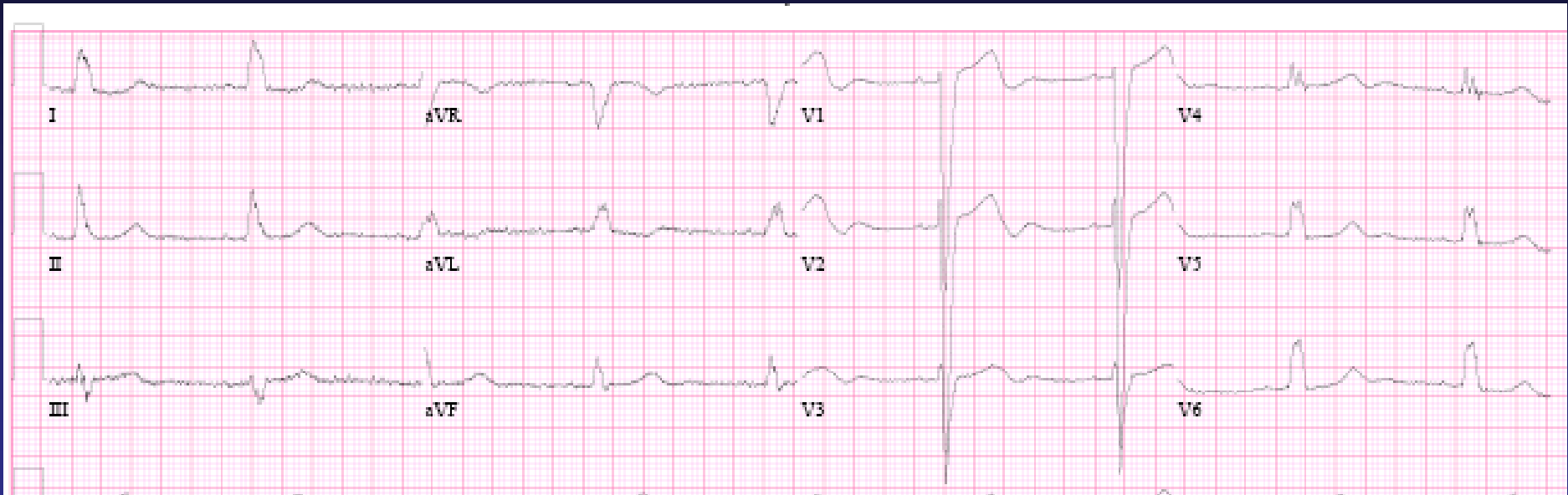
# Case presentation VD 70 y/o ♀

- July 2007: rt. Hip pain, rt. Breast SOL
- Biopsy bone = breast: infiltrating ductal CA grade 3, ER + 70%, PR -, HER +3 (100%)
- August 2007: Osteotomy + rt. Hip replacement
- Femara
- October 2007: Pain, syncope, hypercalcemia
- Metastatic bone spread – skeleton, spine, head



# Cardiovascular

## Hx. of Hypertension



**Echo: LVEDD 46, IVS 10, LVEF 50%, PAP 45**  
**SPECT Imaging – No Ischemia**



# Treatment Plan 11/2007:

- Irradiation to spine + dexacort + analgetics
- Taxol + Herceptin

- Cardiovascular:

Atenolol 25 mg/day

Felodipine 5 mg/day

Furosamide 20 mg/day

???



# January 2008

- **Dyspnea**
- **Echo LVEDD 55 LVEF 40%**  
**Herceptin discontinued**  
**+ Captopril → Losartan; Carvedilol → Bisoprolol**

**Echo 25/2/2008: LVEDD 51 LVEF 50-55%**  
**Feels better**

???



## **March 2008** – Herceptin resumed

- NYHA FC II multifactorial
- Bisoprolol 5mg, Losartan 100mg/d, Fusid 20
- Echo follow up 3/2009 LVEDD 45 LVEF 55%  
6/2009 LVEDD 52 LVEF 50% PAP 27 mm Hg

## **August 2009** – Effort dyspnea NYHA FC III

- Echo: LVEDD 50 LVEF 40% mild MR PAP 51
- Herceptin discontinued, spironolactone added

???



# November 2010

- **Oncological remission**
- **Effort dyspnea NYHA FC III**
- **LVEDD 50 mm, LVEF 52%, mild MR  
impaired relaxation, PAP 30 mm Hg**
- **Bisoprolol 1.25 mg, Valsartan 80, Thiazide  
12.5, Spironolactone 12.5**
- **Low blood pressure, sinus bradycardia, K 5.1**
- **Cardiac rehabilitation**

**What if .....???**

