

Valve-in-Valve for Degenerated Bioprosthesis with Severe Aortic Regurgitation

Victor Guetta

Amit Segev

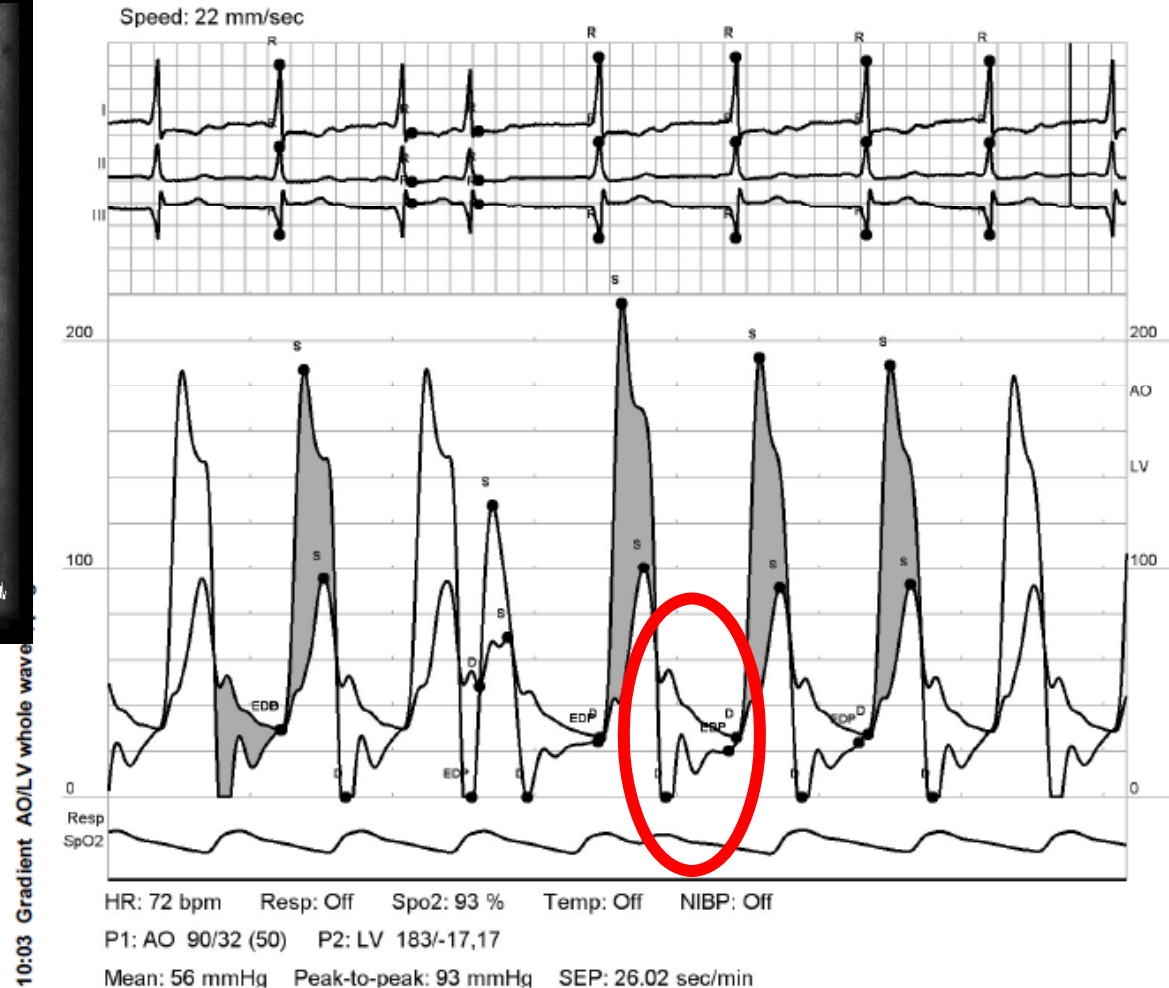
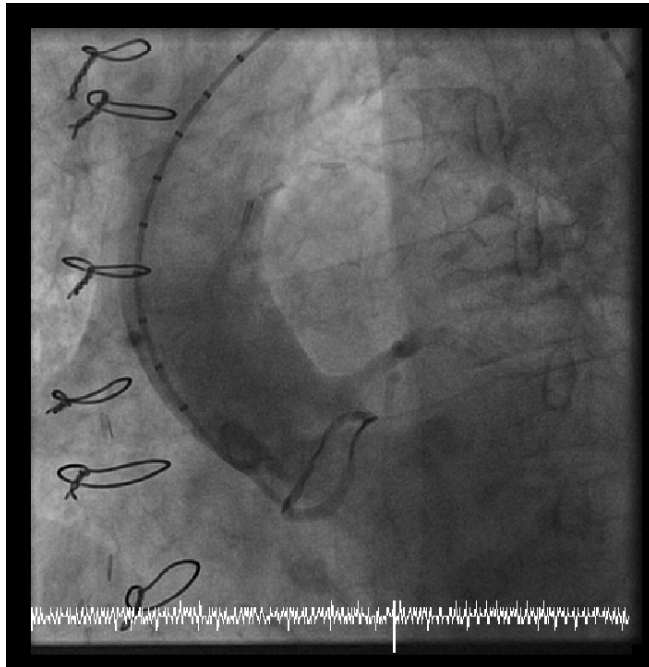
Chaim Sheba Medical Center

Case Presentation

- 81 y-old female
- HTN, dyslipidemia
- 2007 – AVR (Mitroflow 23) + CABG
- 12/2011 – admission for NSTEMI + pulmonary edema
 - Echo – severe AR + mod AS, SPAP - 78
 - PCI to SVG to RCA
 - Intractable heart failure
- TAVI..... – trans-femoral
 - Internal diameter of Mitroflow 23 is 19 mm
 - CoreValve 26

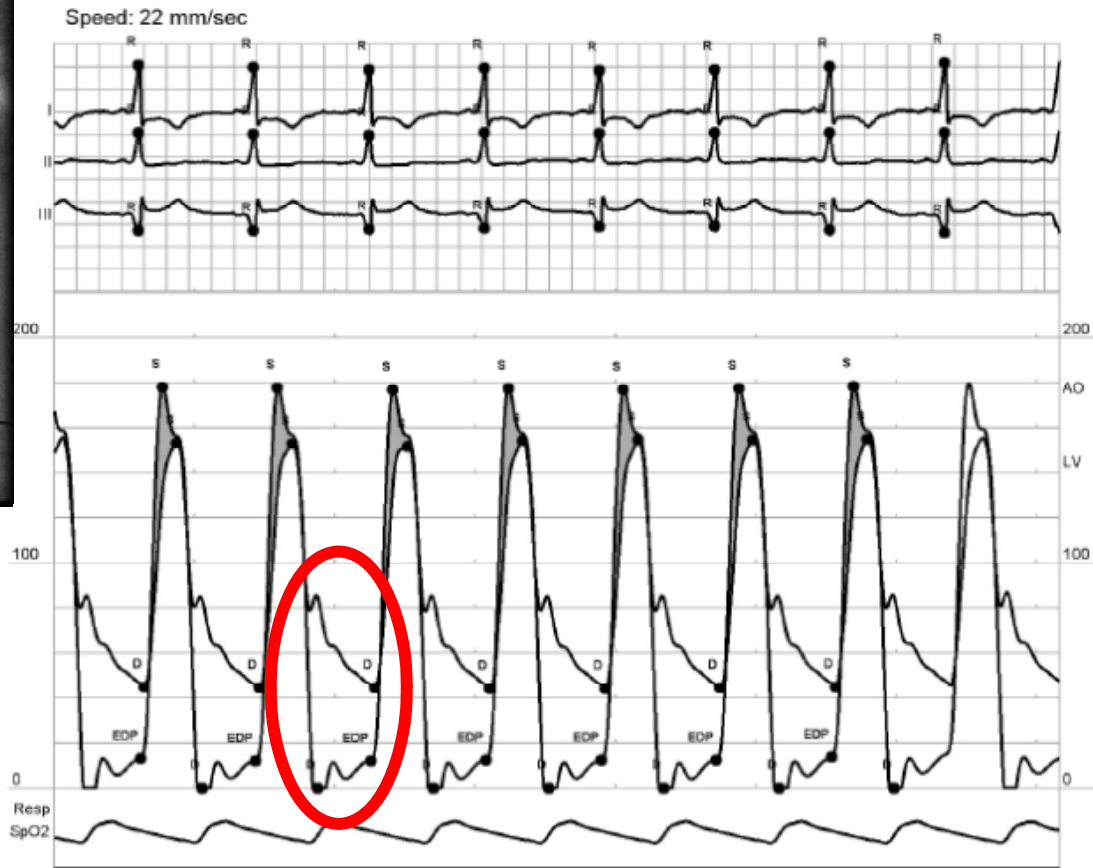
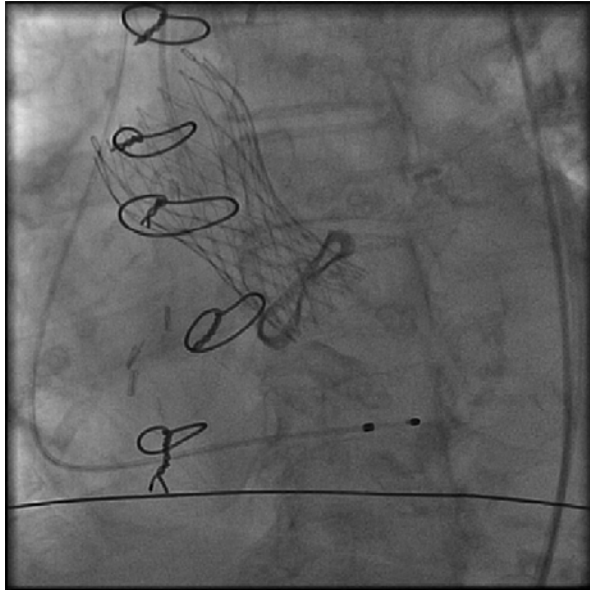
Severe Aortic Regurgitation

LEVDP = Ao diastolic pressure



Post TAVI

Note – Diastolic gradient....



Post Implantation

10:09 Gradient AO/LV whole waves, page 1

HR: 73 bpm Resp: Off Spo2: 96 % Temp: Off NIBP: Off

P1: AO 154/45 (84) P2: LV 178/-19,13

Mean: 21 mmHg Peak-to-peak: 24 mmHg SEP: 20.2 sec/min