

Lady Davis
Carmel Medical Center



Rappaport
Faculty of Medicine

Mitral Valve Disease

Avinoam Shiran, MD

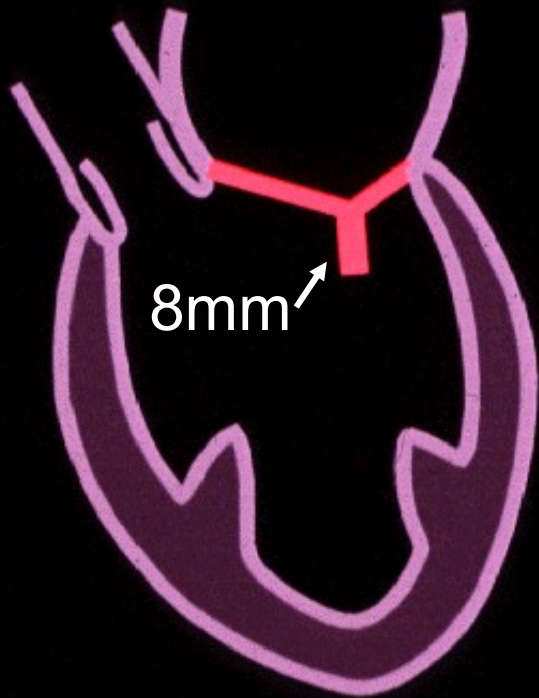
Director, Echocardiography

Department of Cardiovascular Medicine

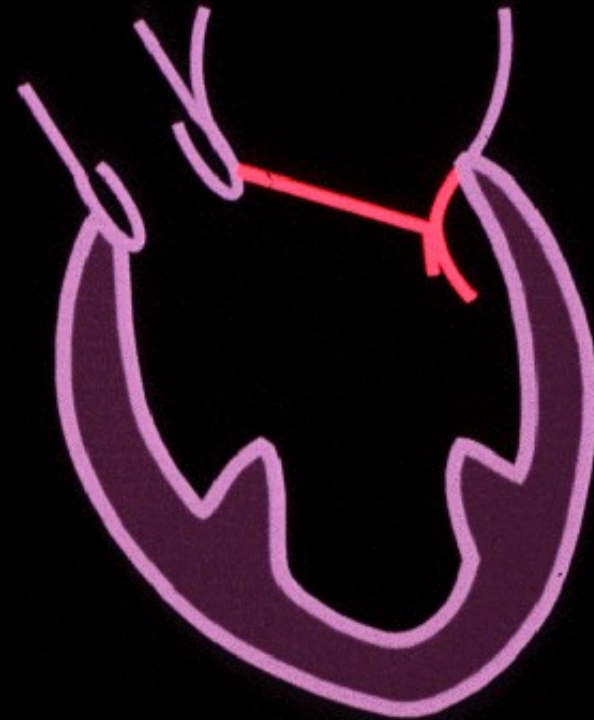
Lady Davis Carmel Medical Center, Technion IIT

Caesarea 11/2008

Abnormal coaptation

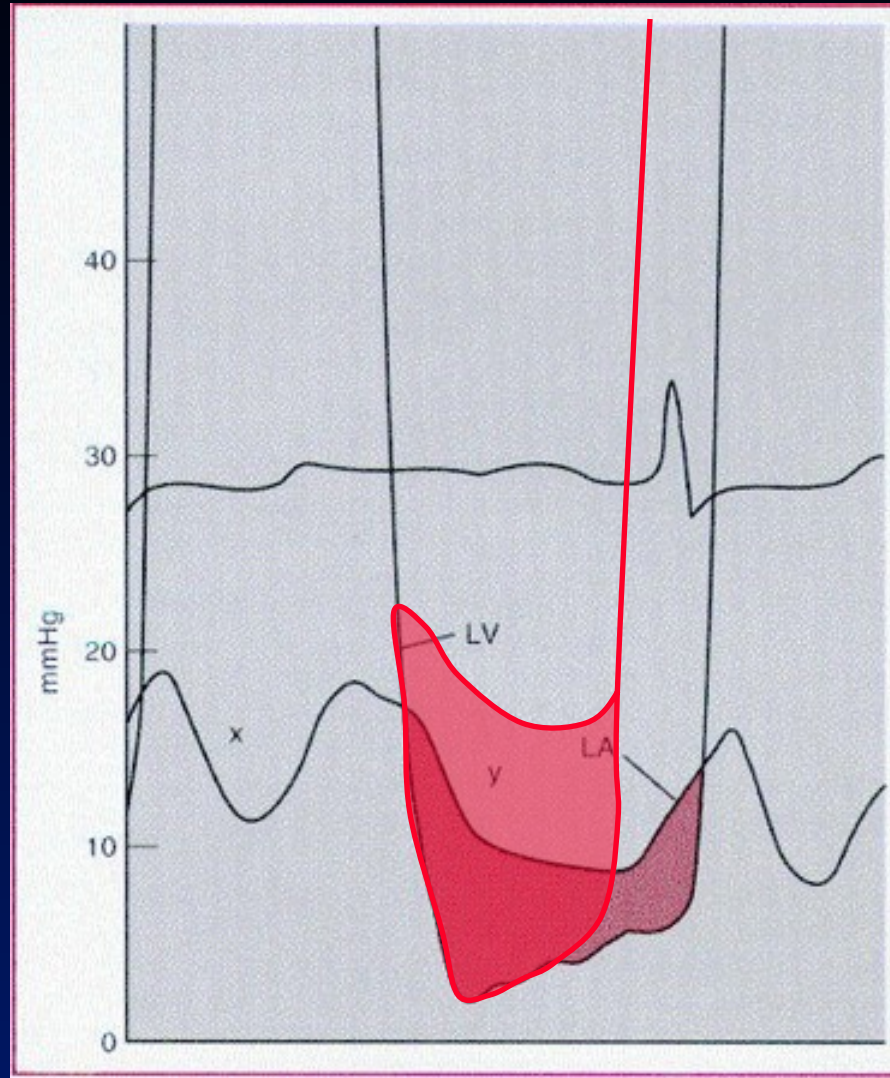


Normal coaptation

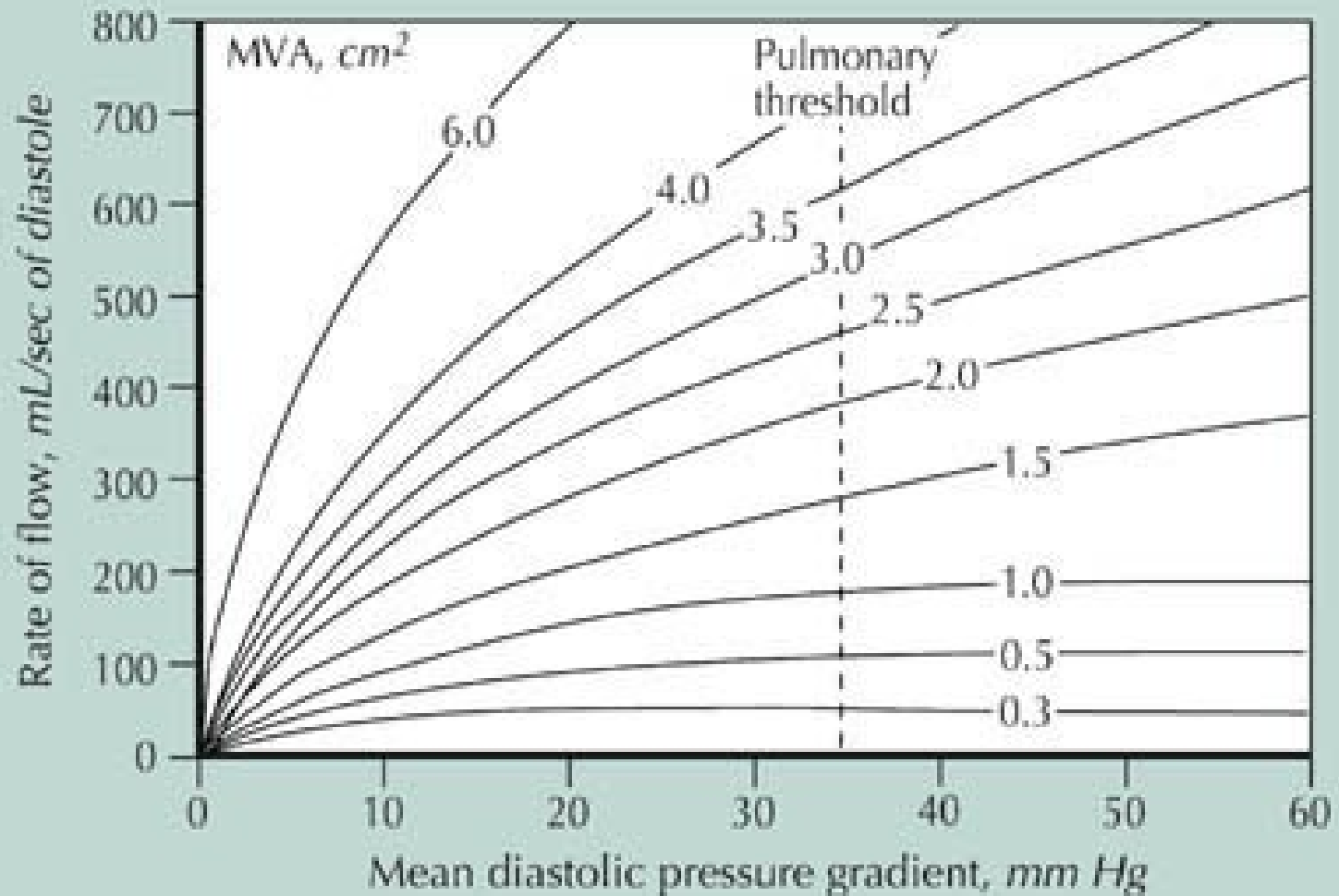


Abnormal coaptation

MS: Pathophysiology



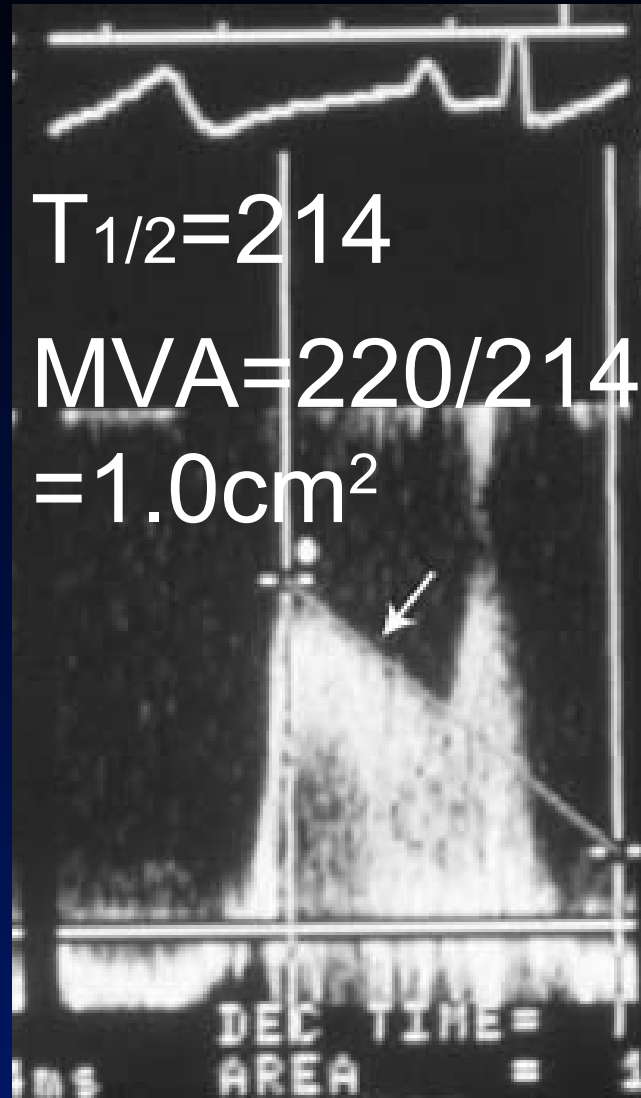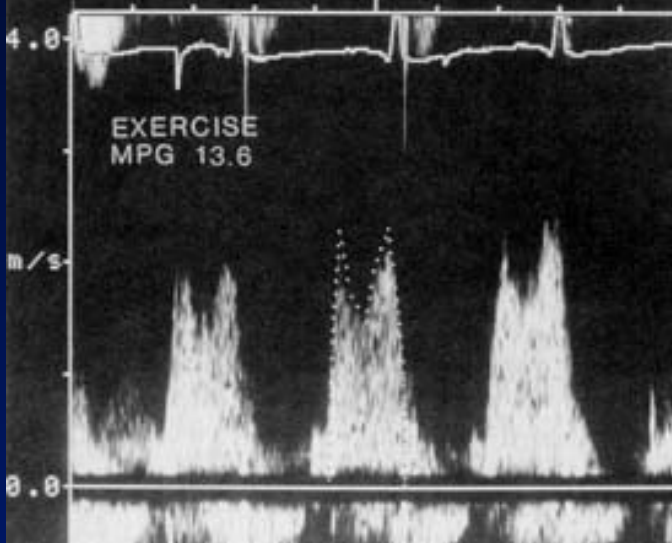
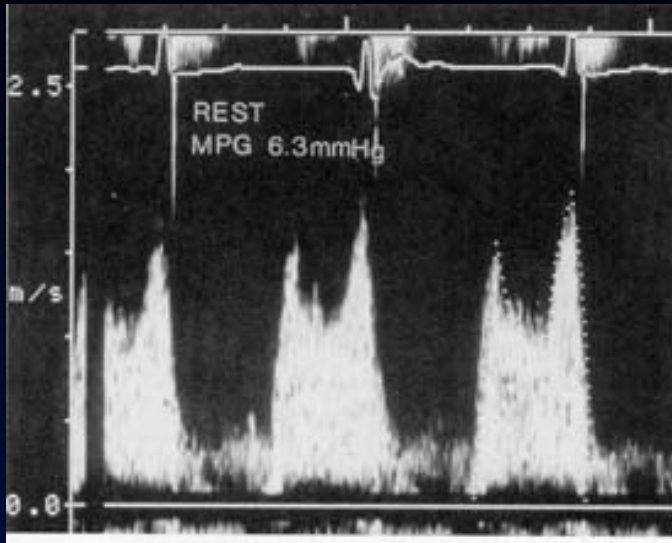
Pathophysiology



Physical findings

- PMI- normal
- RV lift
- 1st heart sound↑
- Opening snap
- Diastolic murmur – presystolic accentuation
- P_2 ↑
- TR (TS)
- CHF

Echo-Doppler



AR, ASD,
→ MVA ↑
LVH → MVA ↓

Medical treatment

- ∇ β blockers (Ca blockers, Digoxin)
 - Diuretics
 - Anticoagulation
- ∇ β arrhythmics/ cardioversion

Balloon valvuloplasty ACC/AHA 2006

Class I

- FC II-IV, $MVA \leq 1.5 \text{cm}^2$, favorable anatomy, no thrombus, $MR < +3$
- Asymptomatic with sys PAP > 50 mmHg at rest, > 60 mmHg during exercise

Class IIa

- FC III-IV, calcified valve, high risk surgery

Balloon valvuloplasty ACC/AHA 2006

Class IIb

- FC I, new onset atrial fibrillation
- FC II-IV, MVA > 1.5 cm² but sys PAP > 60 mmHg, PCWP > 25 mmHg or mean ΔP > 15 mmHG during exercise
- FC III-IV, calcified valve

Surgery

- Open commissurotomy
- MVR
- Tricuspid annuloplasty if >mild TR or tricuspid annulus diameter ≥ 3.5 cm*

Surgery – ACC/AHA 2006

Class I

- FC III-IV, $MVA \leq 1.5 \text{cm}^2$, and PBMV is not an option
- FC III-IV, $MVA \leq 1.5 \text{cm}^2$ and $MR+3-4$
– MVR unless repairable

Class IIa

- MVR: FC I-II, $MVA \leq 1.0 \text{cm}^2$, $\text{sys PAP} > 60 \text{ mmHg}$, and PBMV or repair is not an option

Surgery – ACC/AHA 2006

Class IIb

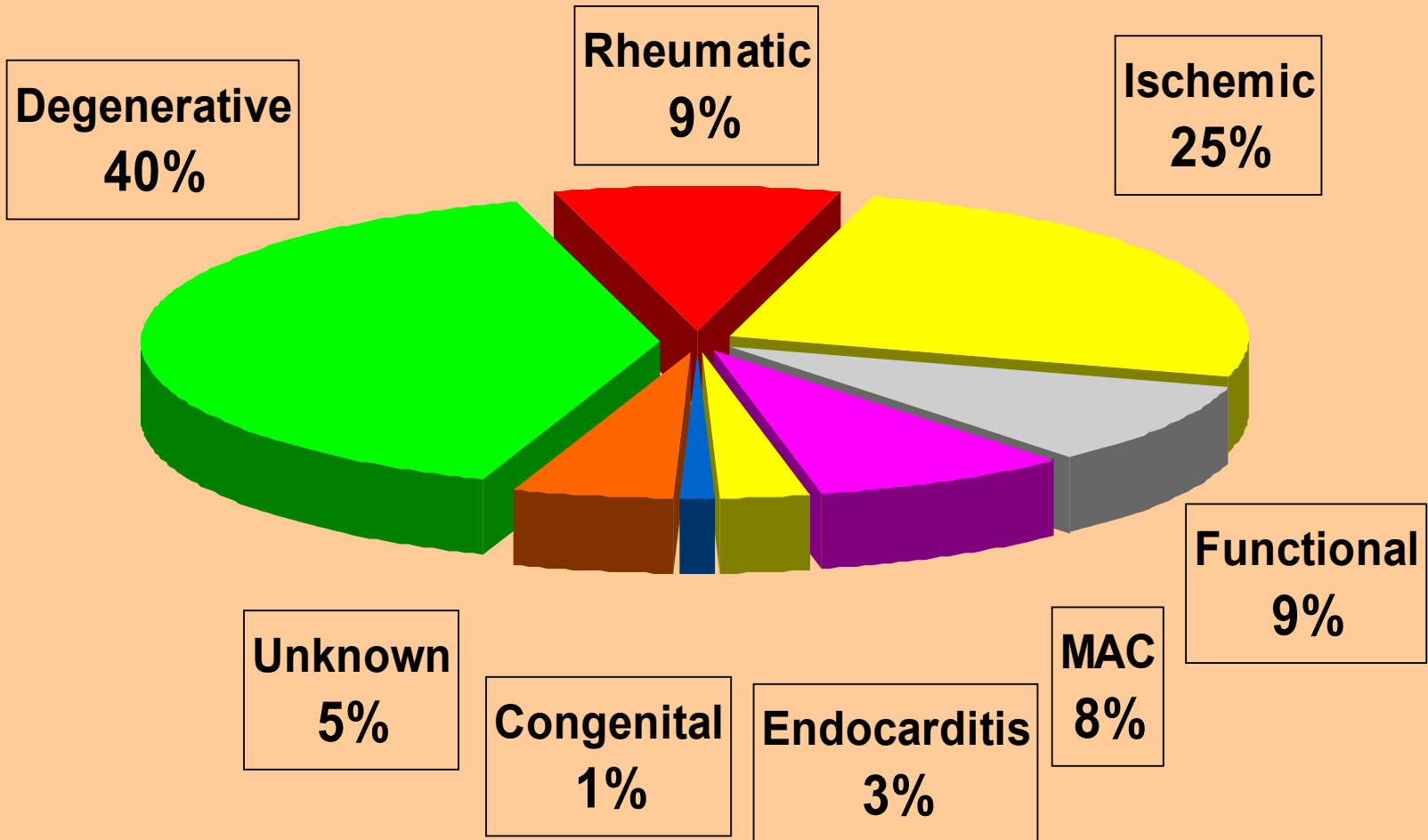
- MV repair for $MVA \leq 1.5 \text{cm}^2$, favorable anatomy and recurrent emboli despite adequate anticoagulation

Acute MR

- Etiology: ruptured papillary muscle, acute ischemic MR, BE, MV repair/replacement failure, ruptured chordae
- Clinical presentation: pulmonary edema and cardiogenic shock. Mitral murmur often inaudible
- Diagnosis: immediate echo
- Rx: IABP±mechanical ventilation, immediate TEE, coronary angio and surgery

Chronic Severe Mitral Regurgitation

Etiology of MR (n=180)



Degenerative Mitral Valve Disease

- “Spontaneous” ruptured chordae
- Myxomatous, MVP, Barlow’s disease
 - Can be genetic: Marfan, rarely- familial, x-linked: Filamin A mutation*
 - Incidence 1-2% (≥ 2 mm PLAX)
 - Dynamic mid systolic click late systolic murmur
 - May progress to severe MR, ruptured chordae, at risk for endocarditis

Pathophysiology of MR

- LV volume overload
- Normal or reduced afterload

| LA size: | Normal | Large |
|----------------|--------|-------|
| LA compliance: | ↓ | ↑ |
| LA pressure: | ↑ | N |
| PA pressure: | ↑ | N |

Physical Examination

- Hyperdynamic/displaced PMI
- LA lift (late systolic)
- S1↓ P2↑ III
- Holosystolic apical murmur
 - Radiates to axilla/LSB
 - Intensity does not necessarily correlate with MR severity
- Diastolic “functional” apical murmur
- TR

MR Severity By Echo

- LA & LV size
- MV anatomy
- Color Doppler mapping: jet area, jet area/LA
- PW
- CW
- Pulmonary venous flow
- Calculated regurgitant volume/fraction & EROA
- PISA
- Vena contracta
- Pulmonary pressure

Assessment of the Severity of MR

| | <u>Mild</u> | <u>Moderate</u> | <u>Severe</u> |
|----------------|----------------------|-------------------------|----------------------|
| LA & LV | normal | LA↑ | LA & LV↑ |
| Jet area | < 4 cm ² | 4-10 cm ² | ≥10 cm ² |
| PV sys flow | normal | blunting | reversal |
| RV | <30 ml | 30-59 ml | ≥ 60 ml |
| EROA | <0.2 cm ² | 0.2-0.4 cm ² | ≥0.4 cm ² |
| RF | <20% | 20-50% | ≥50% |
| Vena contracta | <0.3 cm | | ≥0.7 cm |

Management

Surgery

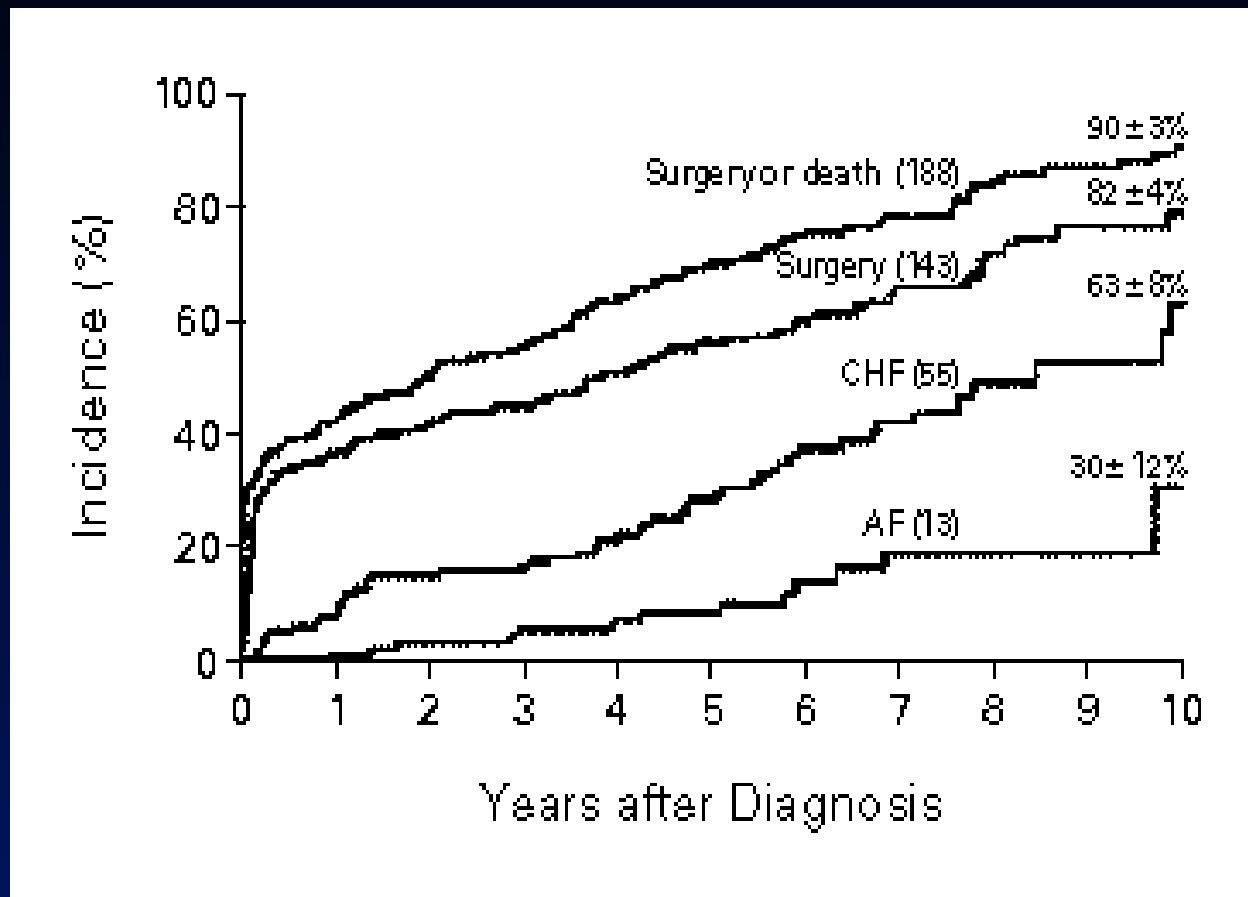


Medical
Treatment

Afterload Reduction in MR

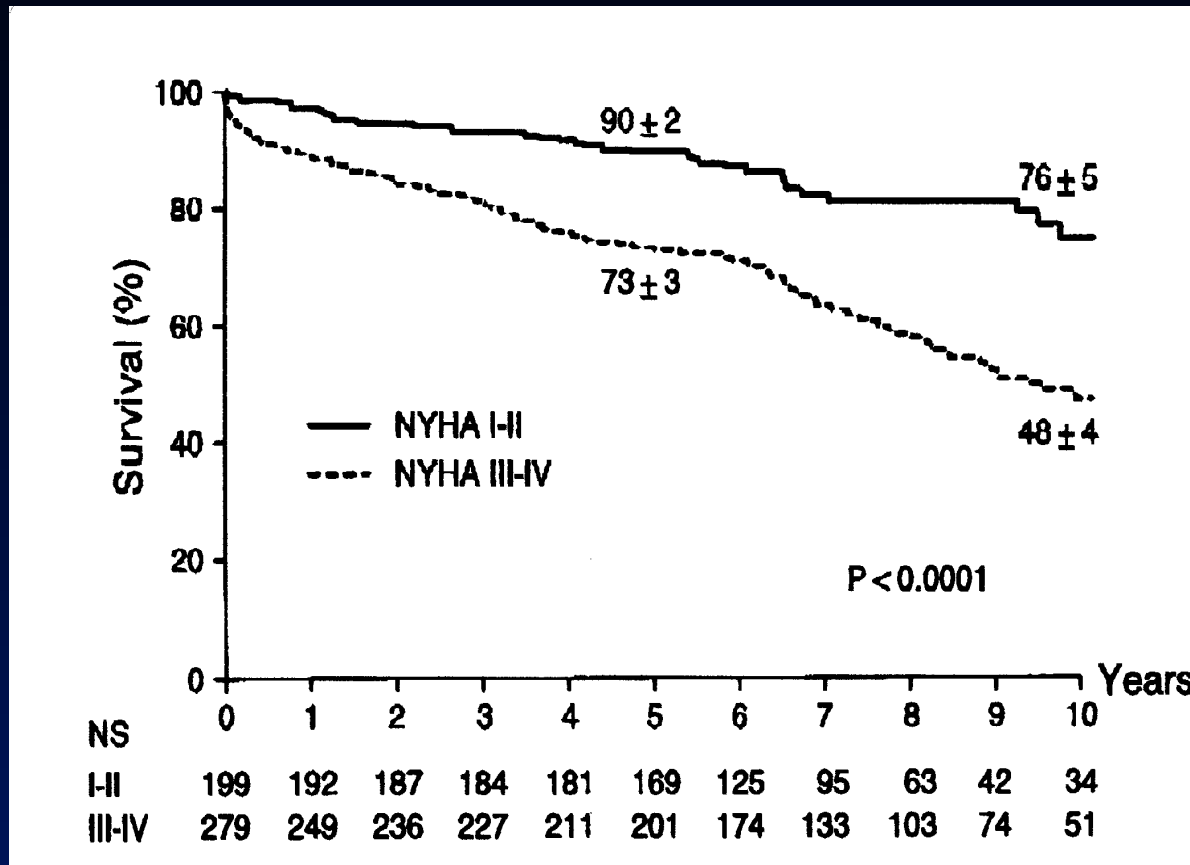
- Role in acute MR
- Role in patients with CHF, LV dysfunction, hypertension
- No data to support use in chronic asymptomatic MR

Clinical Outcome of Mitral Regurgitation Due to Flail Leaflet



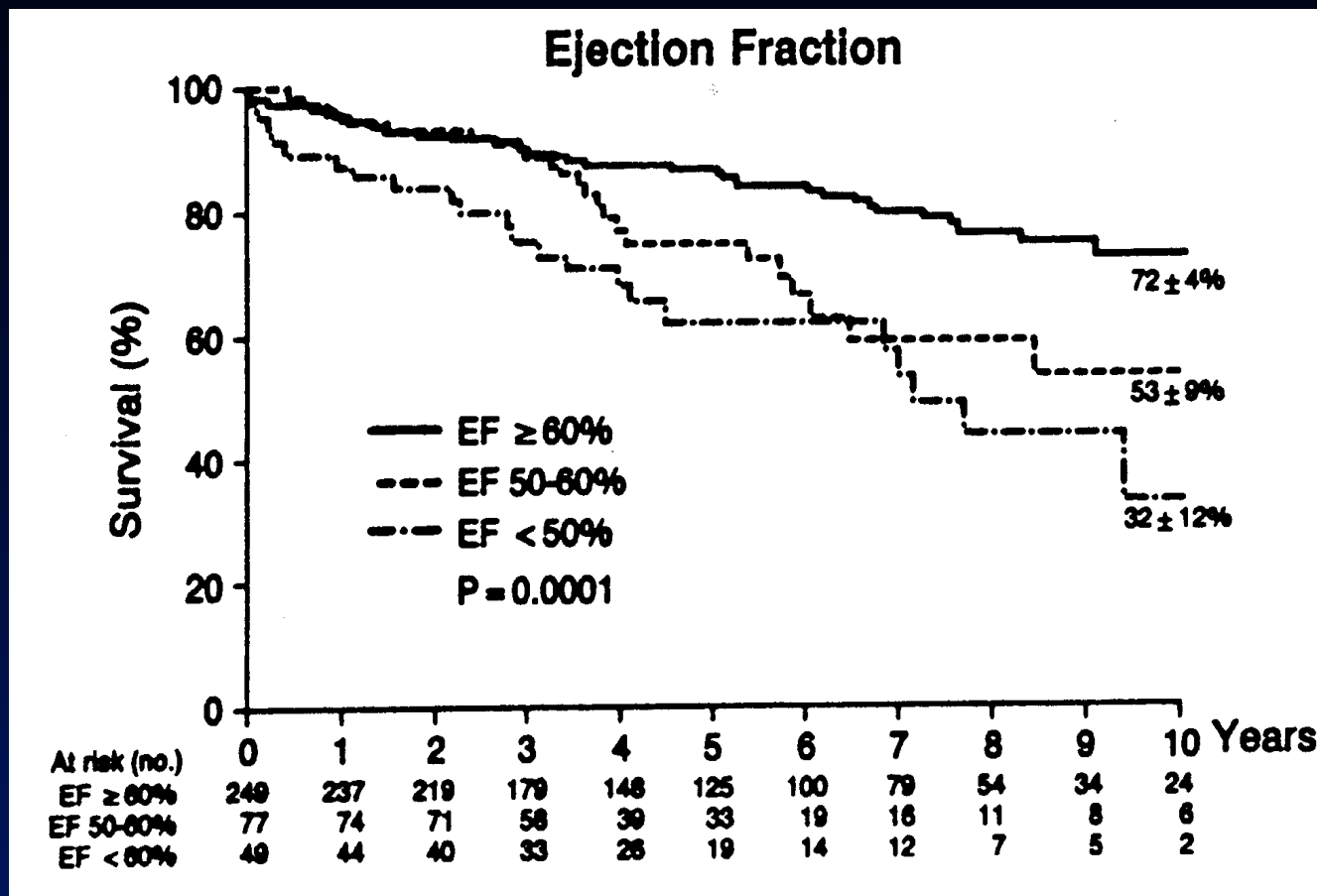
Ling et al, NEJM 96 (Mayo Clinic)

Impact of Preoperative Symptoms on Survival After Surgical Correction of Non-ischemic MR



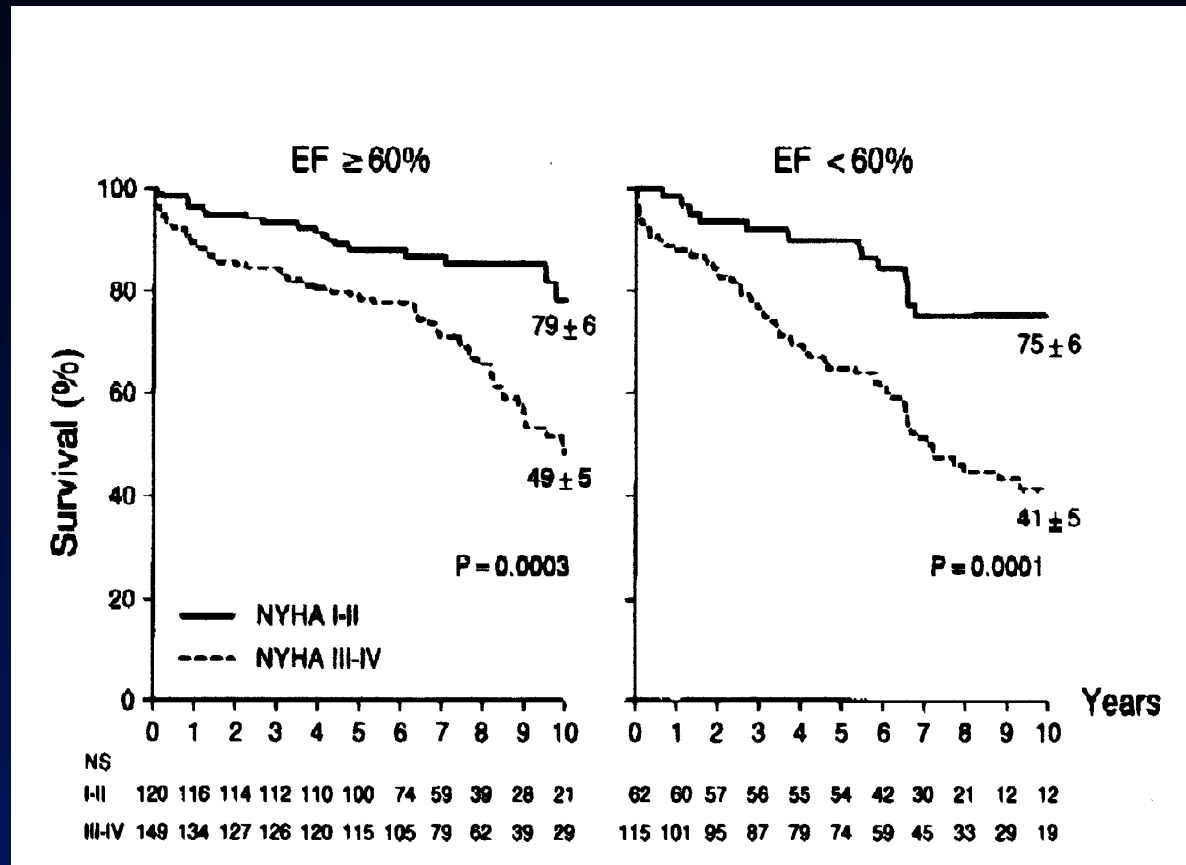
Tribouilloy et al, Circ 99 (Mayo Clinic)

Survival After Surgical Correction of Non-ischemic MR by Preoperative EF



Enriquez-Sarano et al, Circ 94 (Mayo Clinic)

Survival After Surgical Correction of Non-ischemic MR by Preoperative EF and Symptoms



Tribouilloy et al, Circ 99 (Mayo Clinic)

When to Operate?

- **Symptoms ($F_c \geq II$)**
- **EF < 60%**

MV Surgery ACC/AHA 2006

Class I

- **Acute symptomatic severe MR**
- **Chronic severe MR, FC \geq 2, EF \geq 30% and/or LVEDD $>$ 55MM**
- **Asymptomatic chronic severe MR, EF 30-60%, LVEDD \geq 40mm**
- **Repair is better than replacement**

MV Surgery ACC/AHA 2006

Class IIa

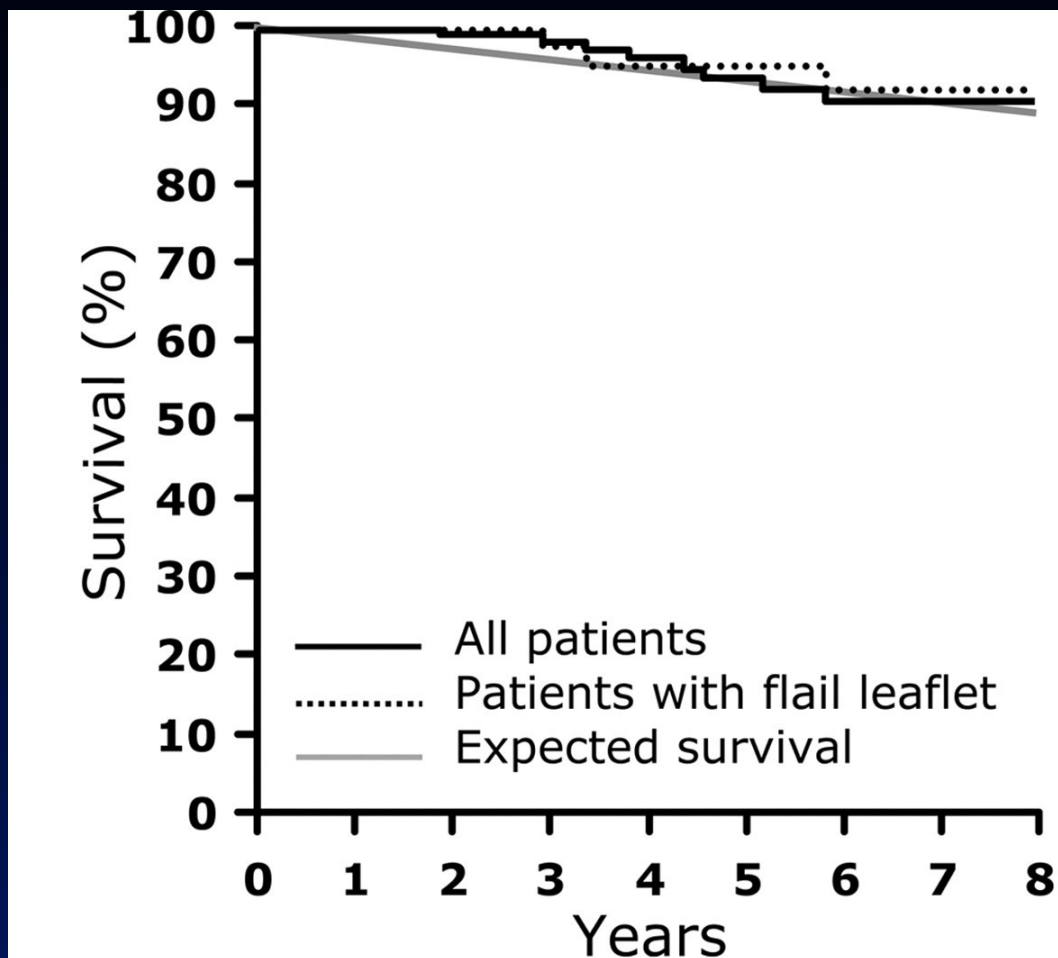
- MV repair for asymptomatic severe MR, EF>60%, repair success>90% (IIb Eu)
- New onset AF
- Sys PAP>50mmHg at rest, >60mmHg during exercise
- Chronic severe MR (primary), FC 3-4, EF<30% or LVEDD>55mm and repair is highly likely

MV Surgery

Class IIb

- MV repair for secondary severe MR, FC 3-4 despite optimal therapy (+CRT), EF<30% (IIa Eu)

Survival of Asymptomatic Severe MR with Watchful Waiting According to Guidelines



All patients

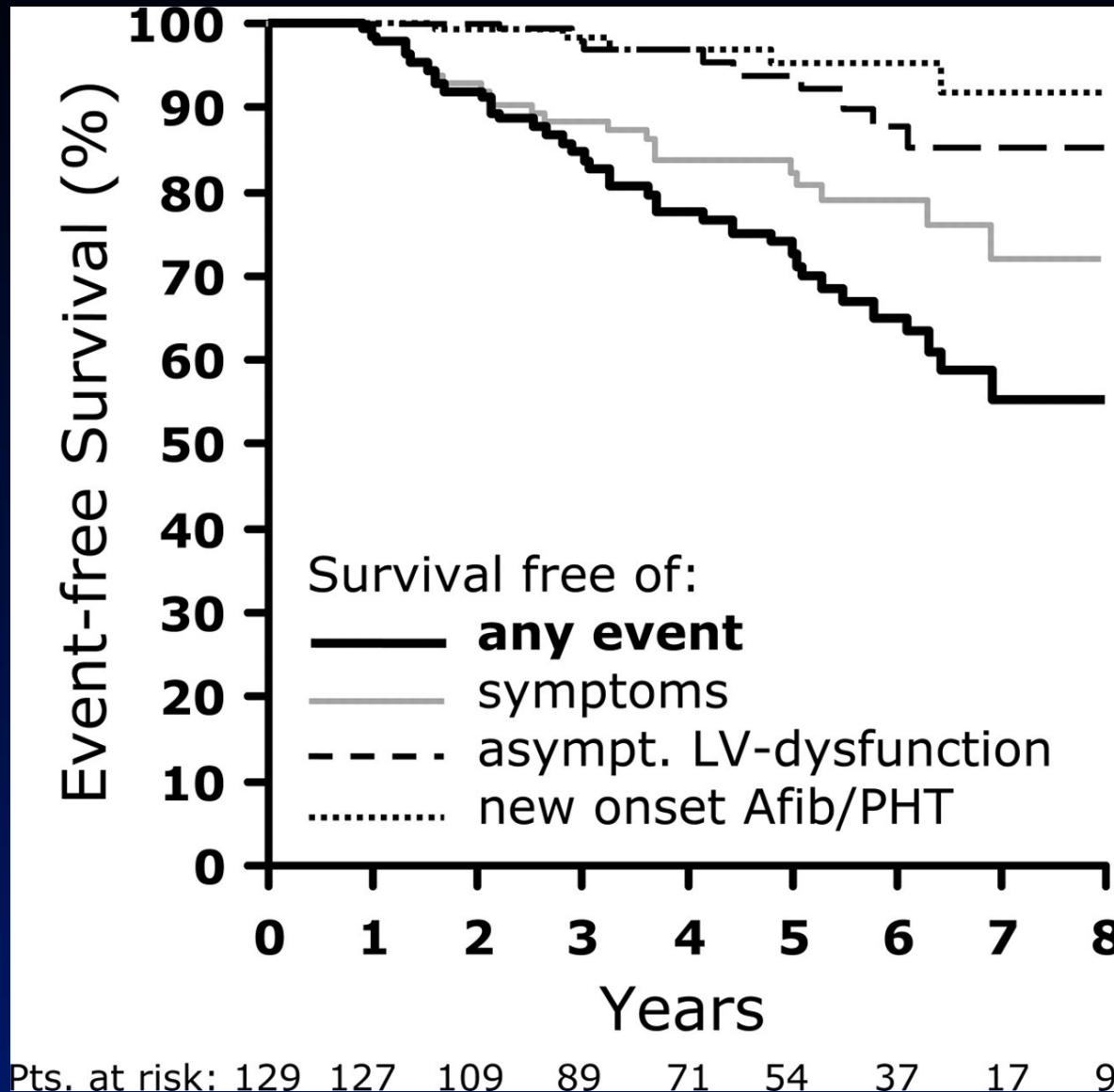
Pts. at risk: 129 129 118 103 87 70 53 24 10

Patients with flail leaflet

Pts. at risk: 56 55 53 43 37 32 28 10 4

Rosenhek et al,
Circ 2006

Event-Free Survival of Asymptomatic Severe MR with Watchful Waiting




24/38 pts with events had symptoms

Rosenhek et al,
Circ 2006

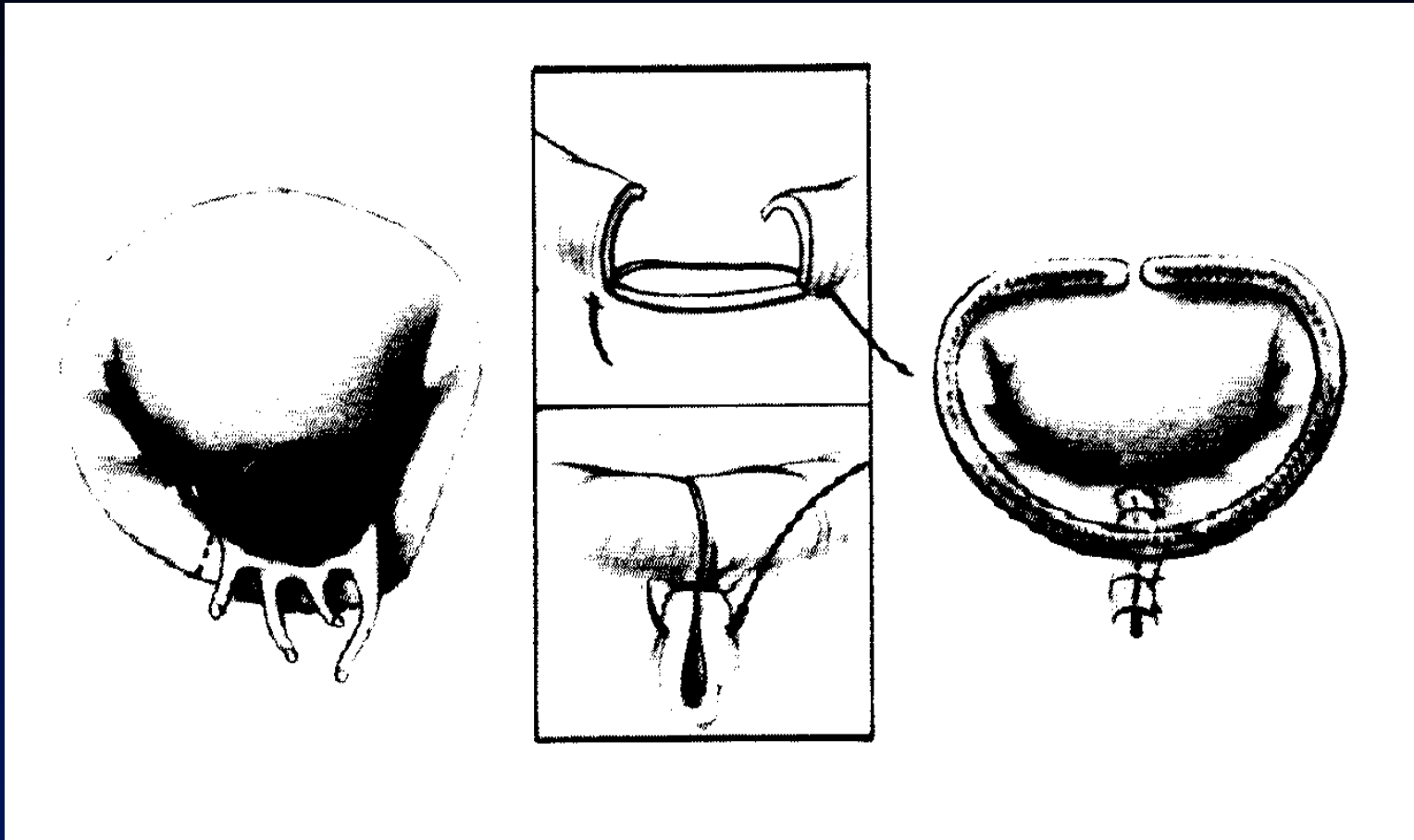
Why Repair?

“Valve replacement is simply exchanging one disease with another”

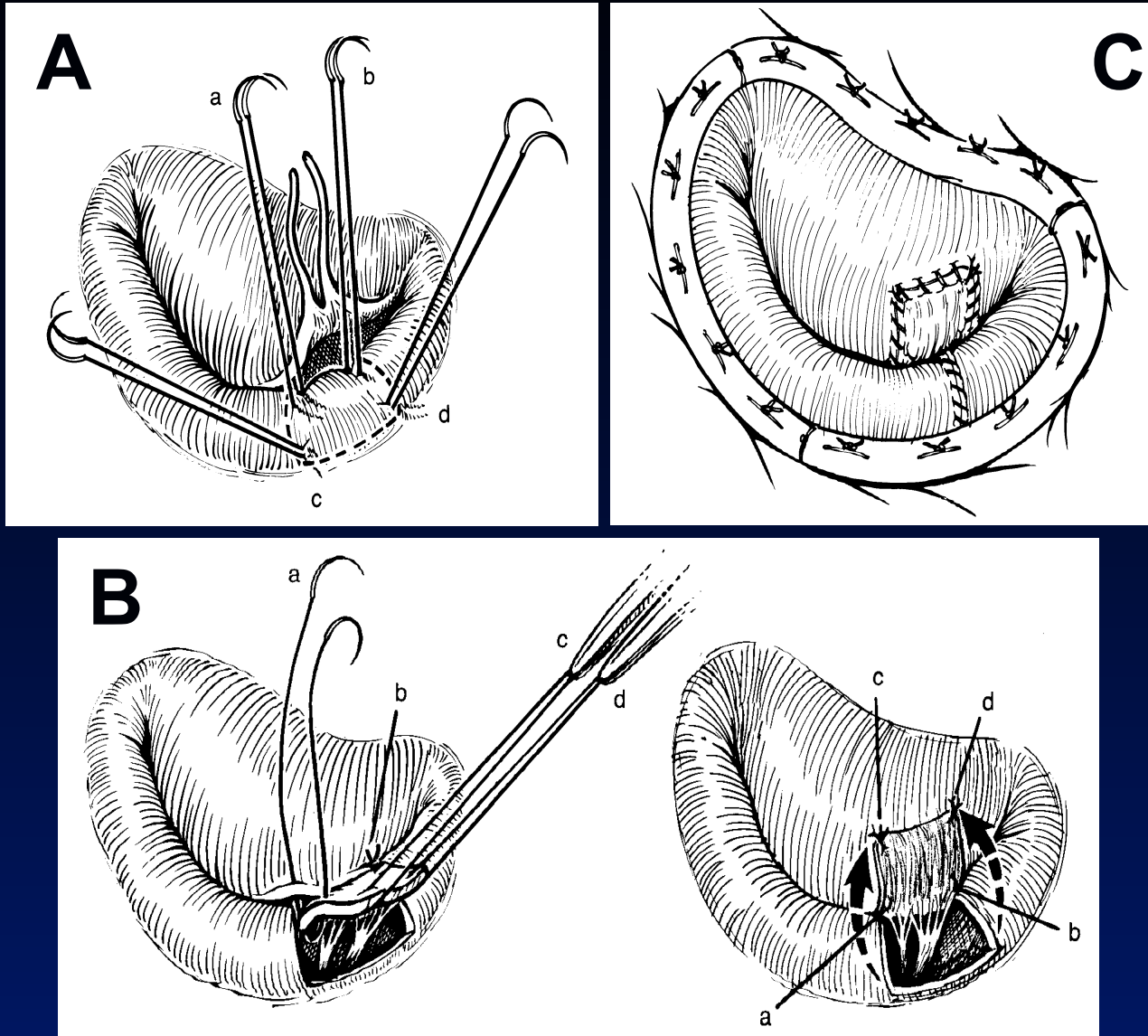
Mitral Prosthetic Ring Annuloplasty



Posterior Leaflet Repair With Quadrangular Resection



Anterior Leaflet Repair: Chordal Transposition



Low Probability of Successful Repair

- Extensive bileaflet prolapse
- Extensive anterior leaflet involvement
- Posterior leaflet involvement >50%
- Significant MAC
- papillary muscle rupture
- Rheumatic MR
- Congenital
- Prior repair

Intraoperative TEE for Mitral Valve Repair

Preop:

- Assess severity of MR
- Define mechanism of MR and anatomy of MV
- Detect associated important findings (TR, AV dis, etc.)

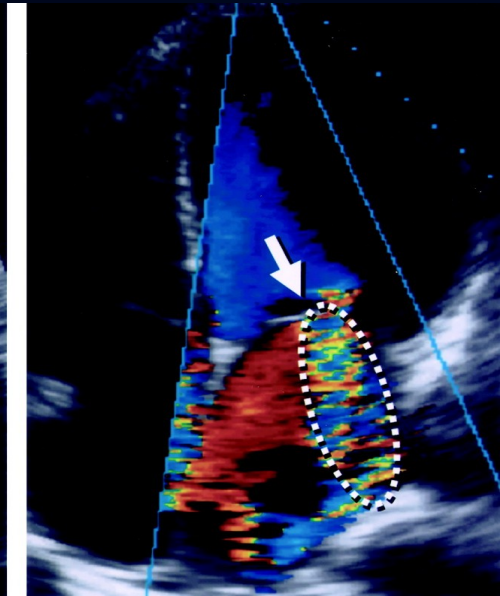
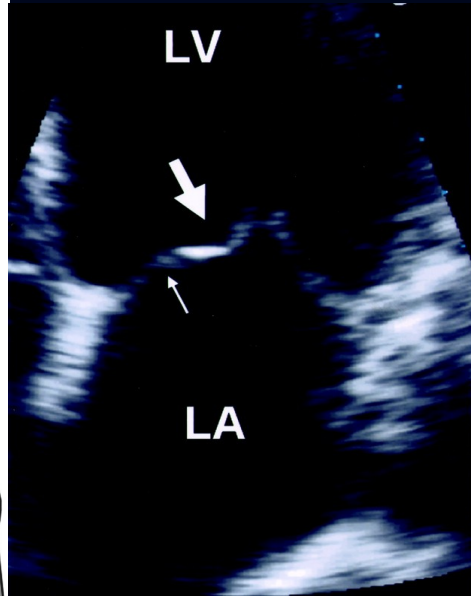
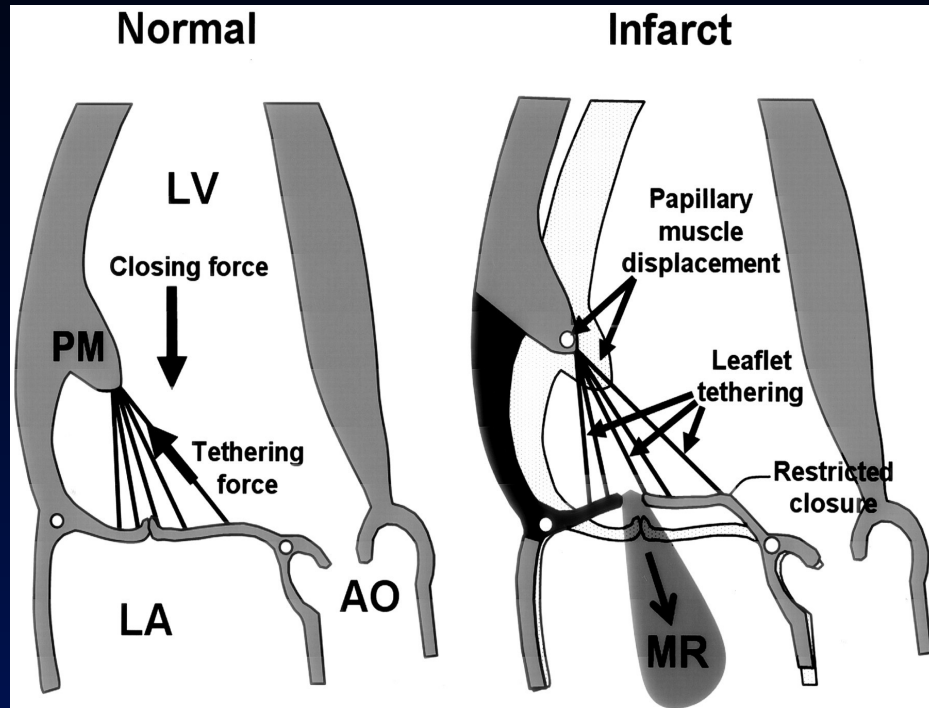
Postop:

- Detect residual MR/ Assess anatomical adequacy
- Detect outflow tract obstruction
- Residual air, LVF, volume status, others

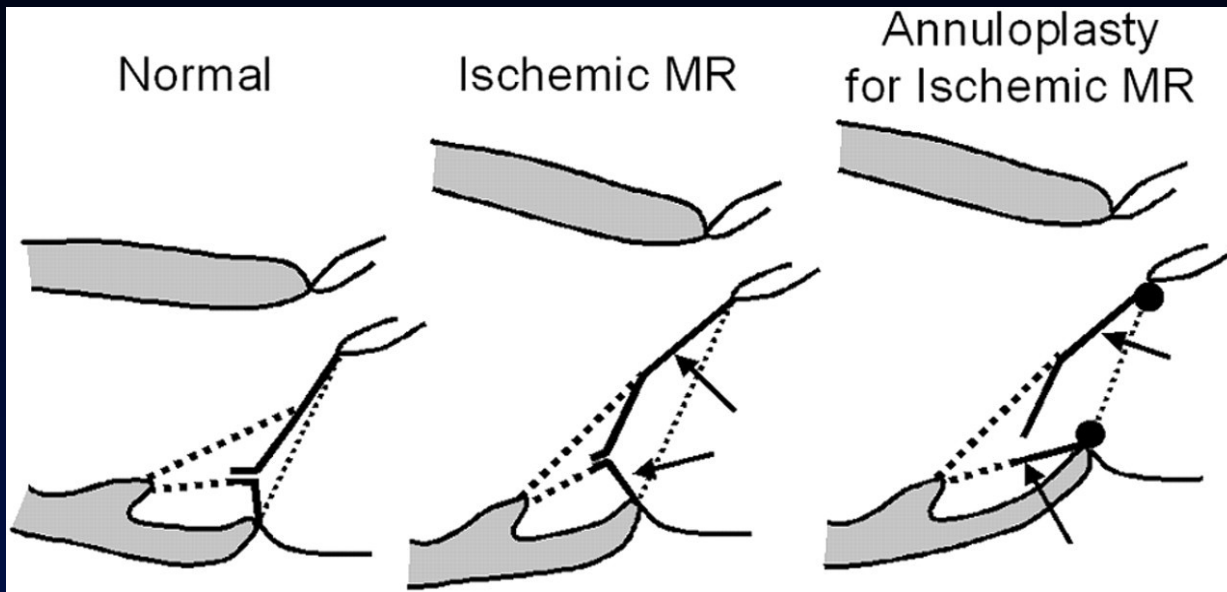
Ischemic Mitral regurgitation

- Dynamic, not static
- Predicts poor survival and CHF
- Increased operative mortality (11%-28%)
- Indication for surgery?
- Type of surgery?

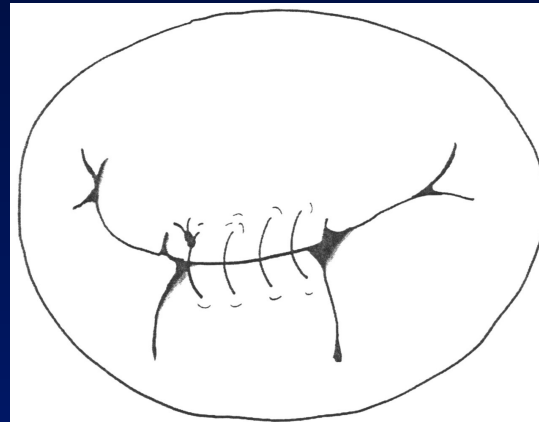
Pathophysiology of Ischemic MR



Repair of Ischemic MR

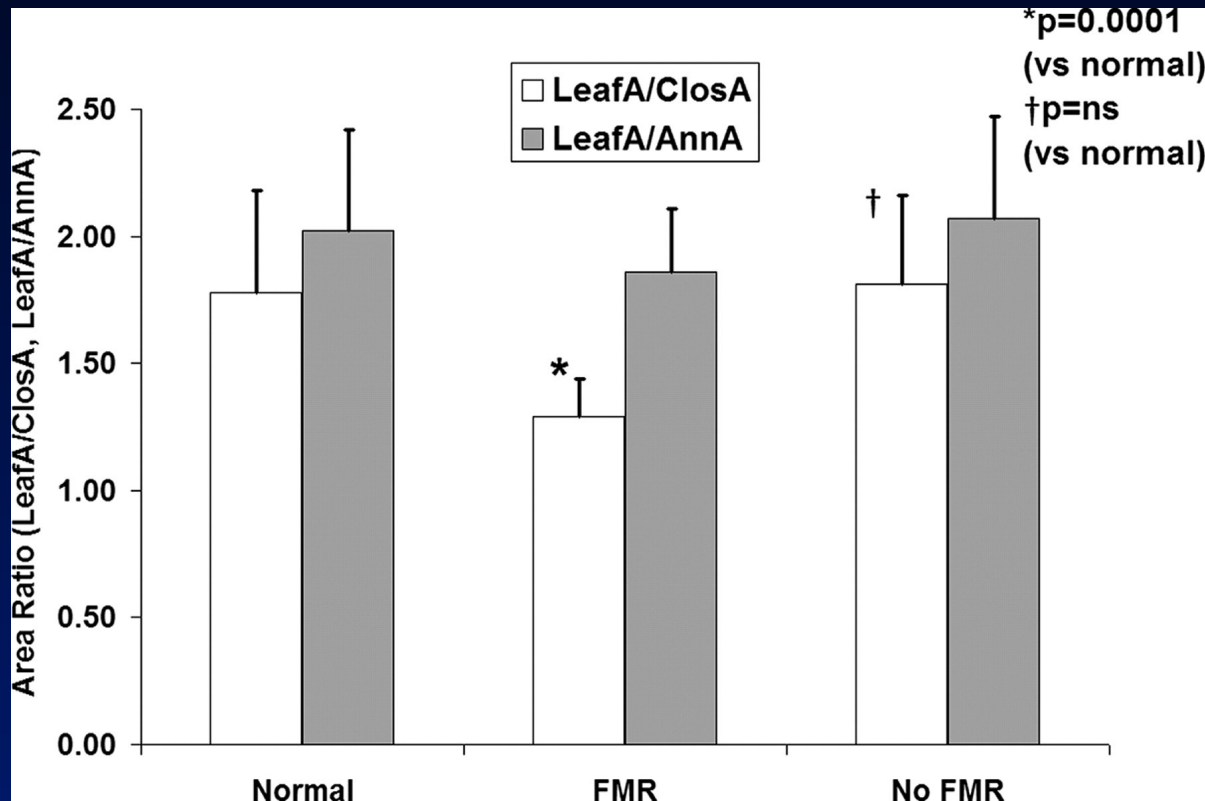
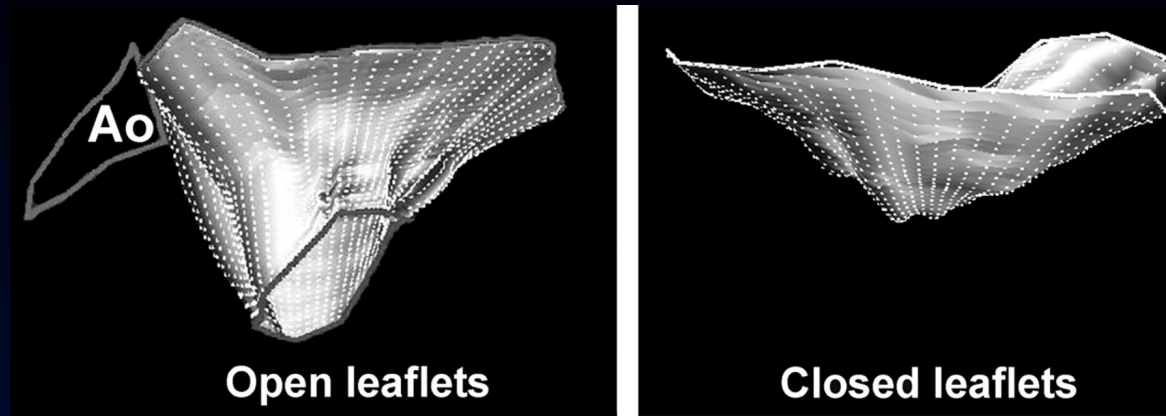


Undersized ring annuloplasty



Alfieri edge to edge repair

Insufficient Leaflet Area in Ischemic MR



Chaput et al, Circ 2008

Mechanical Valves

- Durable (>40 years with SE valves)
- Thrombogenic – requires life long anticoagulation: INR 2.5-3.5 ± aspirin

Complications

- Major bleeding: 0.2-2.2%/y
- Thromboembolism: 2-3%/y
- PV thrombosis (stuck valve): 0.35%/y

Stuck Prosthetic Valve

- High suspicion (INR↓, dyspnea/CHF)
- Echo (TEE), fluoroscopy
- Thrombolysis or surgery

Other PV Complications

- “The dark side of the moon” (TEE necessary)
- Leaks (paravalvular usually)
- Hemolysis
- Endocarditis
- Rare mechanical failure

Valve Selection

- Mechanical valve
 - Long expected lifetime (age < 40 years)
 - Previous dysfunctional tissue valve
 - Anticoagulation required anyway (AF)
 - Renal failure, dialysis

Valve Selection

- Bioprosthesis
 - Short expected lifetime (age \geq 65 years)
 - Unreliable anticoagulant risk
 - Previous thrombosed valve
 - Anticoagulant intolerance
 - Pregnancy anticipated

1) Which is true in ischemic MR?

- a) It is caused by papillary muscle dysfunction
- b) Revascularization alone will usually solve the problem
- c) MV annuloplasty with an undersized ring is a durable solution
- d) MVR with a bioprosthesis with leaflet preservation is a good solution for severe ischemic MR
- e) Ischemic MR is always under-estimated by intra-op TEE because of the unloading effect of anesthesia

2) Which patient will you send for surgery?

- a) Asymptomatic severe MR, normal LV contraction, diffuse bileaflet prolapse
- b) Obesity, HTN, dyspnea, MVP (P2), late systolic MR
- c) Severe MR, ruptured chord to P3, normal LV contraction, dyspnea when climbing 3 flights of stairs
- d) FC3, DCM with EF=20% and severe functional MR

3) Which is true for MVP?

- a) MVP is best appreciated in 4CV
- b) May be associated with a mutation in the the Filamin A gene
- c) MVP with severe MR is an indication for BE prophylaxis
- d) Common in young women (15-20%)
- e) When associated with a ruptured chord – better to replace the valve and not repair, because other chords may rupture after surgery